Introduction to Neuroimaging

BRAIN

Aaron S. Field, MD, PhD
Neuroradiology
University of Wisconsin–Madison

Updated 3/12/07

Brain Imaging: “The Big 10”

- Infarction
- Hemorrhage
- Infection
- Tumor
- Trauma
- Dementia
- MS
- Epilepsy
- Cranial neuropathy
- Orbits / Ophtho dx

Acute Ischemic Stroke Imaging

- Confirm diagnosis
- Triage for therapy (risk / prognosis)
  - Rule out hemorrhage
  - Assess damage: location, pattern, extent
  - Is there salvageable brain ("penumbra")?
- Follow outcome
  - Vessel patency, ultimate infarct size, hemorrhagic transformation

CT Signs in Early MCA Ischemia

Hyperdense MCA

Insular Ribbon

Lentiform Nucleus

Pathophysiology of Ischemic Injury:
Duration and Degree of ↓ CBF

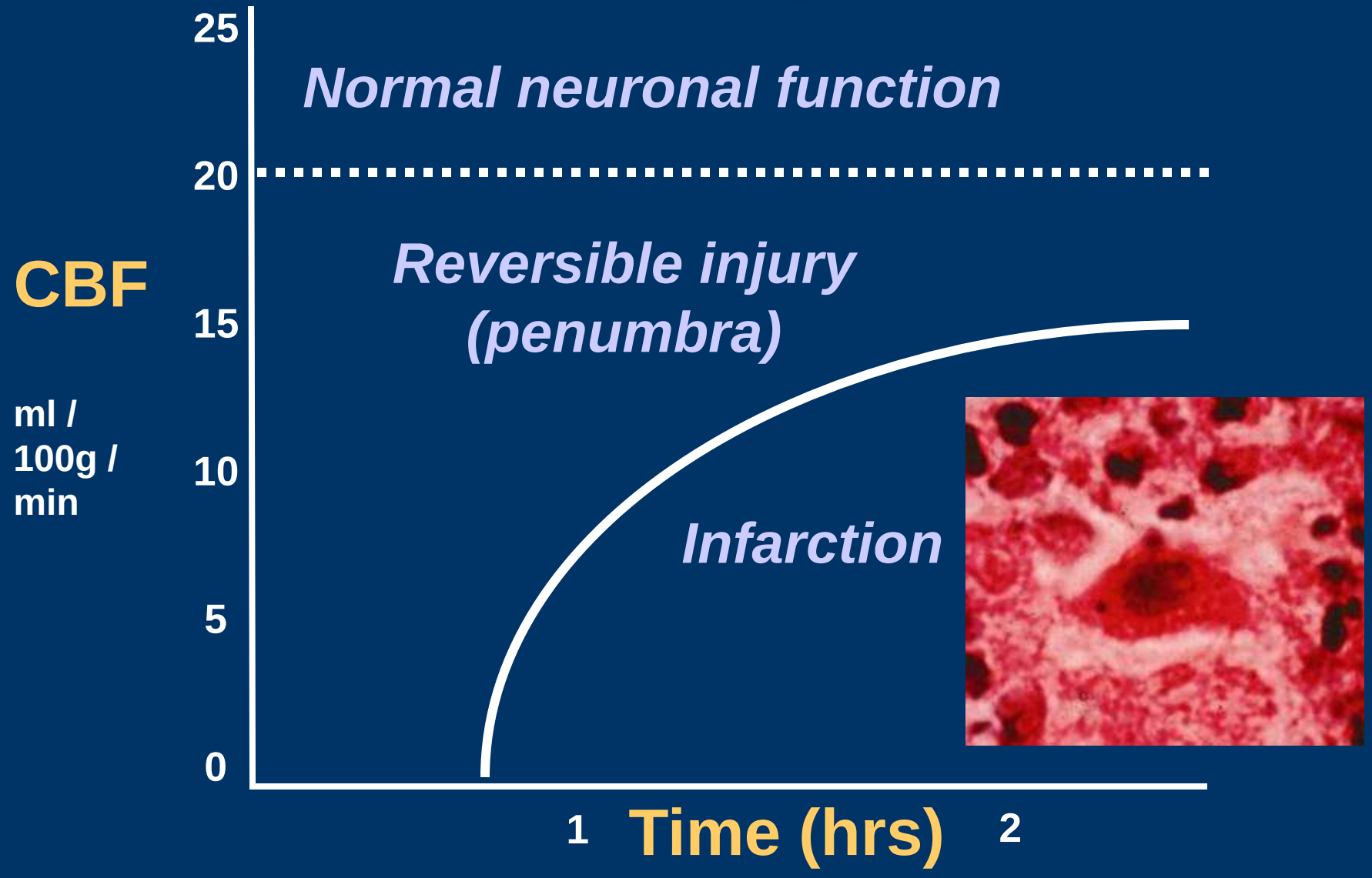

MRI in Stroke Intervention
"The 4 P's"

MRA

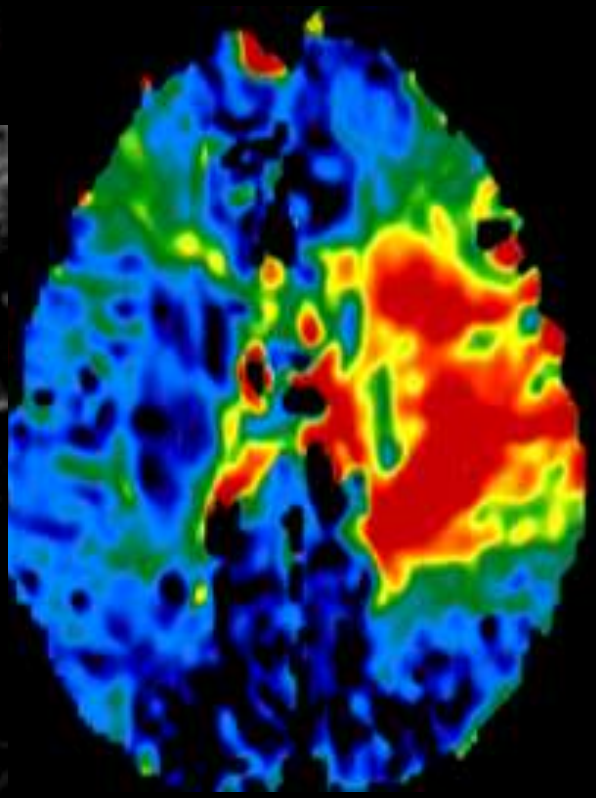

Perfusion MR

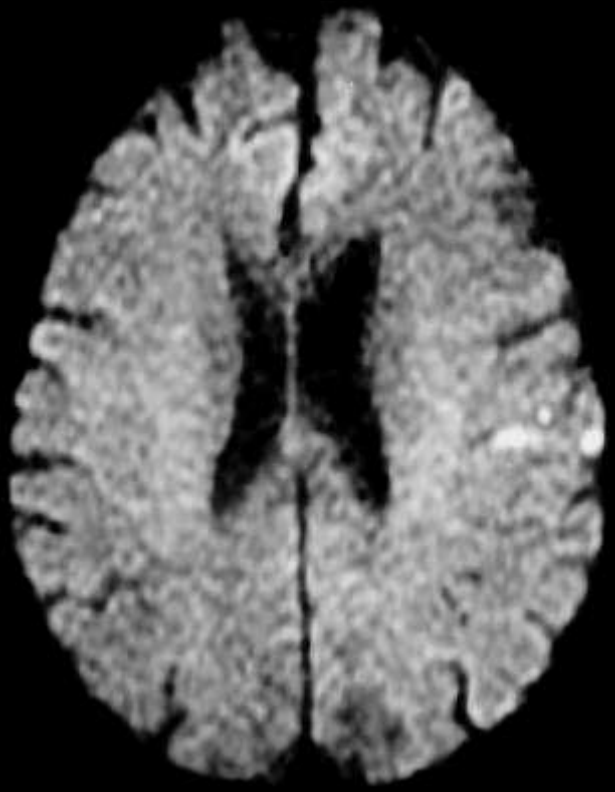

Diffusion MR

Pipes → Perfusion → Parenchyma

"Penumbra"

Rowley *AJNR* 22(4); 599-601, 2001

MCA Infarct

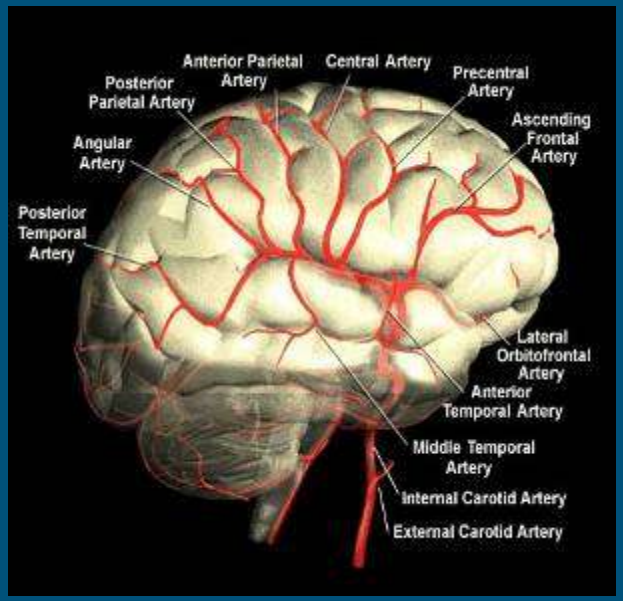
Anterior Parietal Artery
Central Artery
Precentral Artery
Posterior Parietal Artery
Ascending Frontal Artery
Angular Artery
Posterior Temporal Artery
Lateral Orbitofrontal Artery
Anterior Temporal Artery
Middle Temporal Artery
Internal Carotid Artery
External Carotid Artery

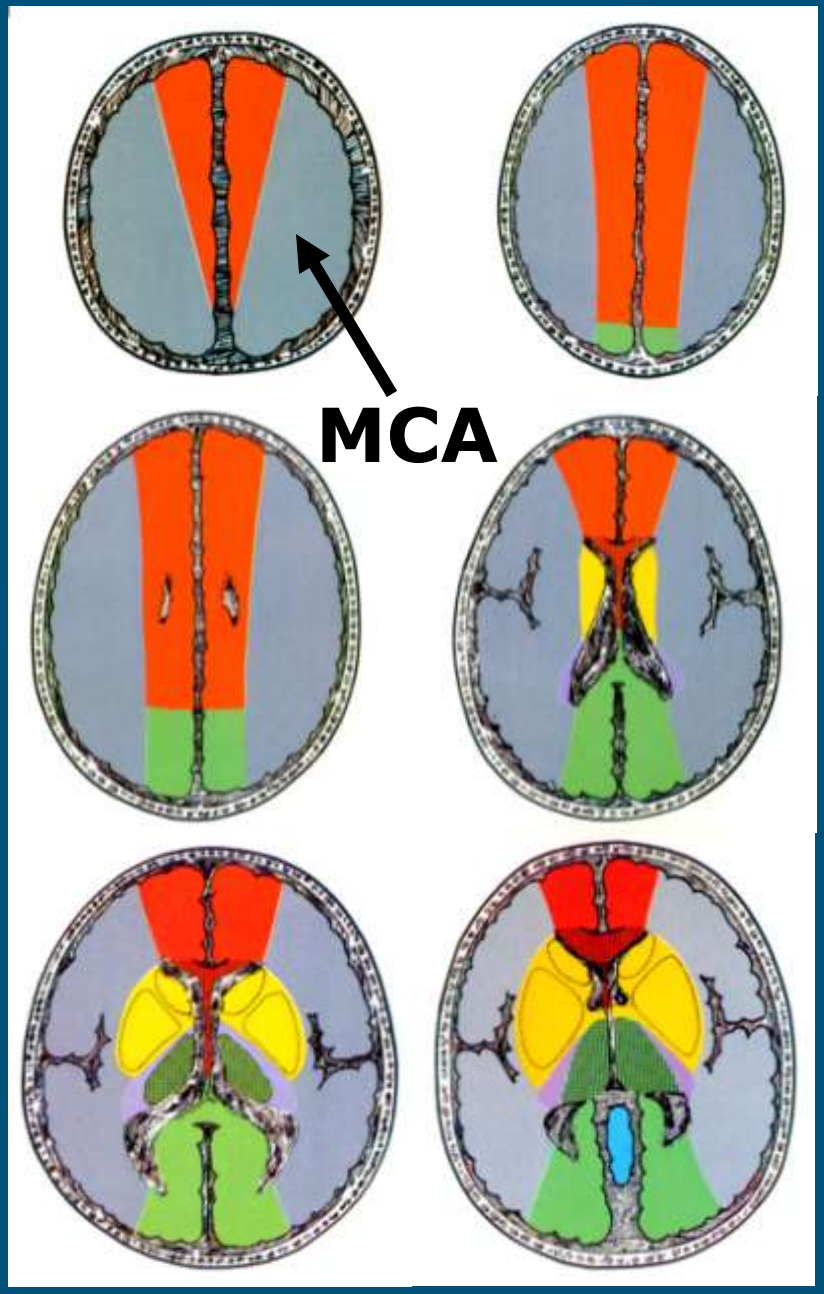
MCA

PCA Infarct

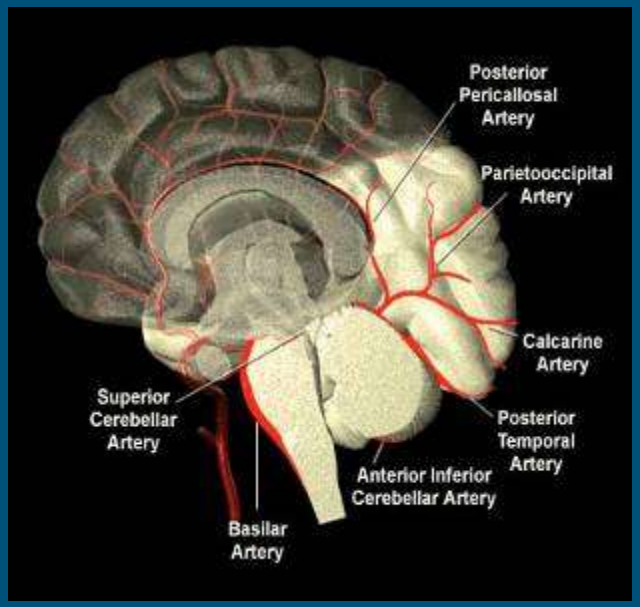
Posterior Pericallosal Artery
Parietooccipital Artery
Calcarine Artery
Posterior Temporal Artery
Anterior Inferior Cerebellar Artery
Superior Cerebellar Artery
Basilar Artery

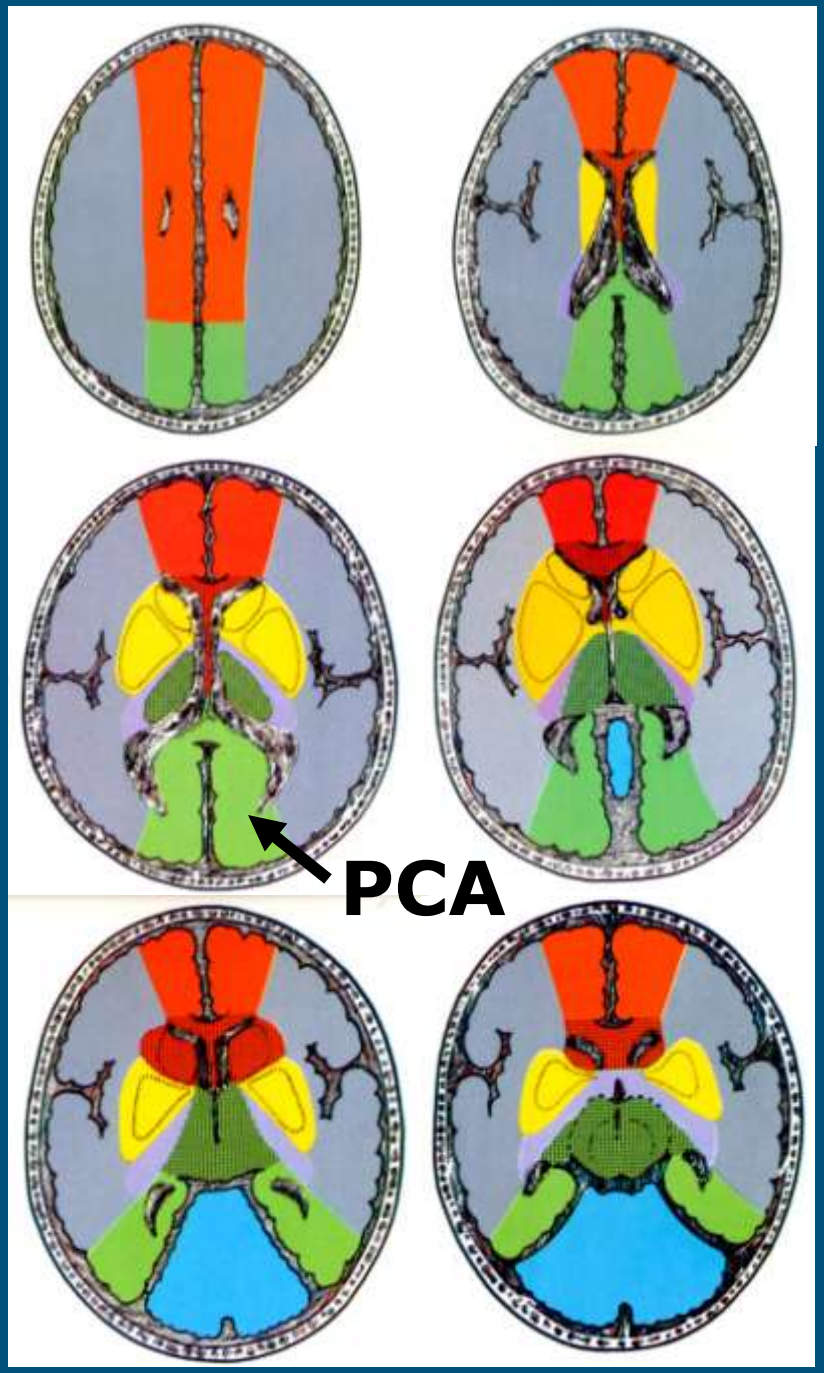
PCA

ACA Infarct

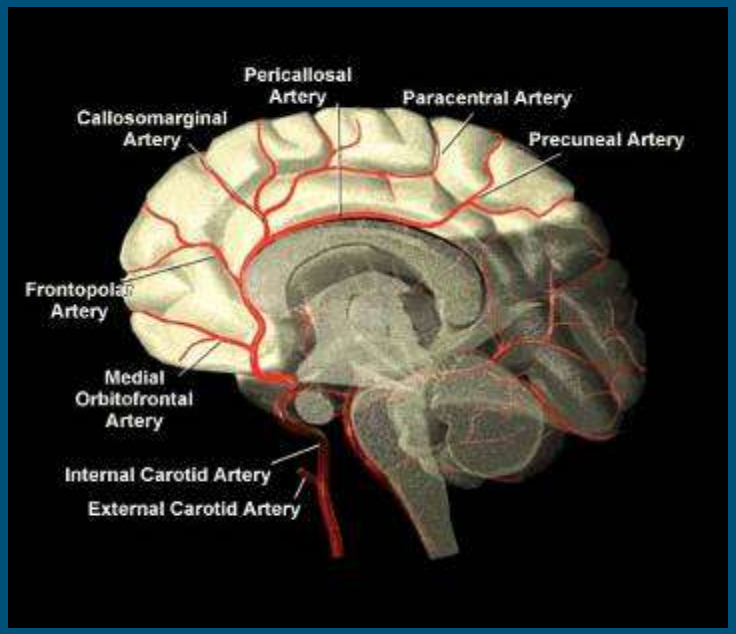
Pericallosal Artery
Paracentral Artery
Callosomarginal Artery
Precuneal Artery
Frontopolar Artery
Medial Orbitofrontal Artery
Internal Carotid Artery
External Carotid Artery

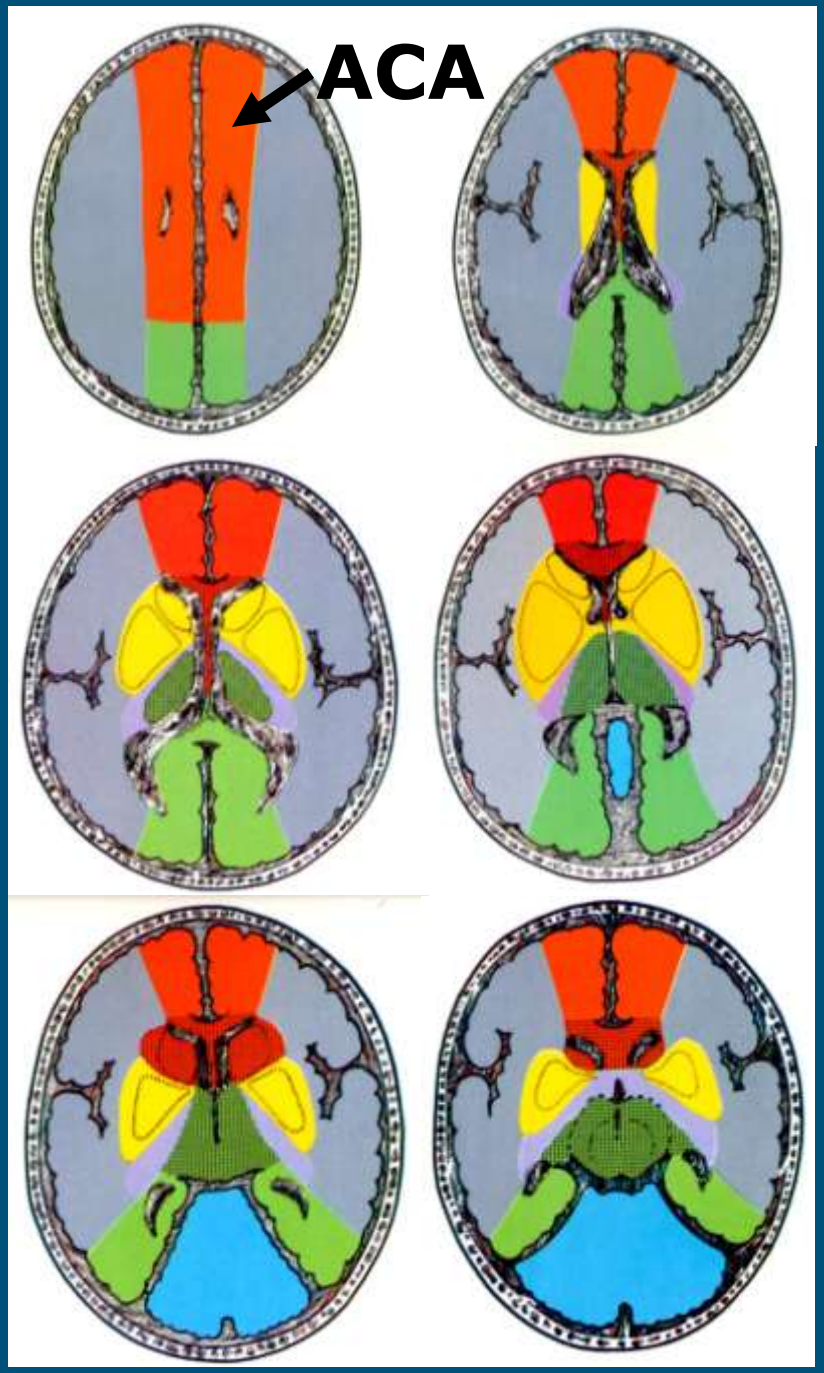
ACA

Brain Imaging: “The Big 10”

- Infarction
- Hemorrhage
- Infection
- Tumor
- Trauma
- Dementia
- MS
- Epilepsy
- Cranial neuropathy
- Orbits / Ophtho dx

Cerebral Hemorrhage

- Trauma
- Ruptured aneurysm
- Hypertensive
- Hemorrhagic transformation of ischemic infarction (esp. venous)
- Venous infarction
- Tumor
- Vascular malformations
- Angioinvasive infection
- Amyloid angiopathy

Cerebral Hemorrhage

Acute intraparenchymal hematoma

Cerebral Hemorrhage

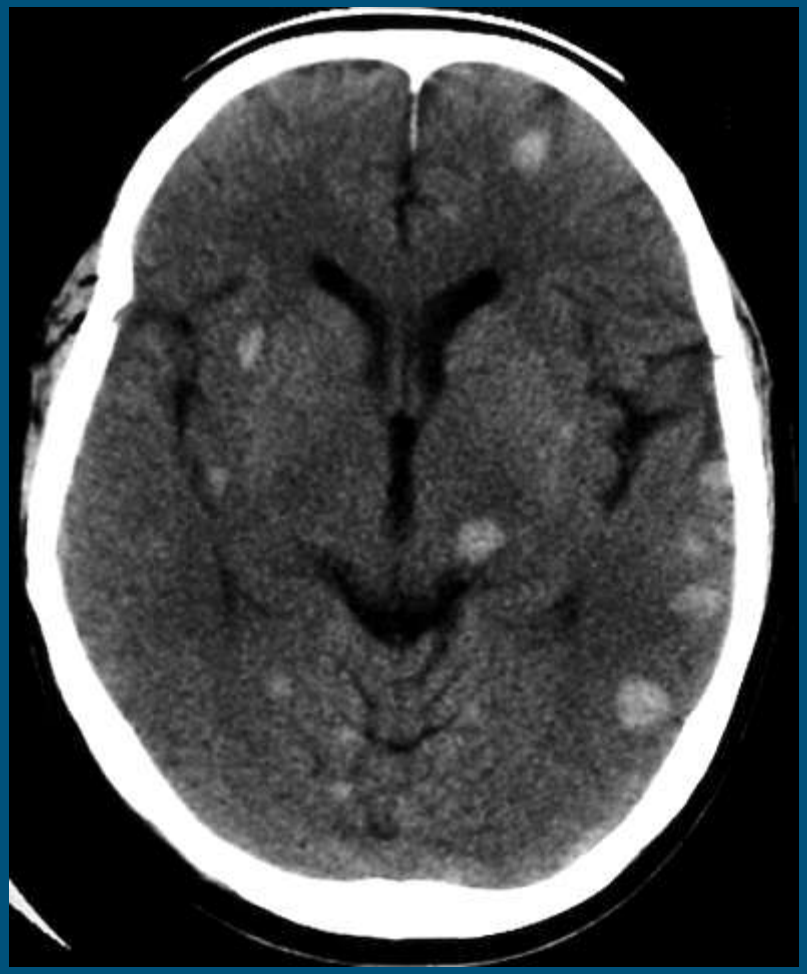

Hemorrhagic melanoma metastases

Cerebral Hemorrhage

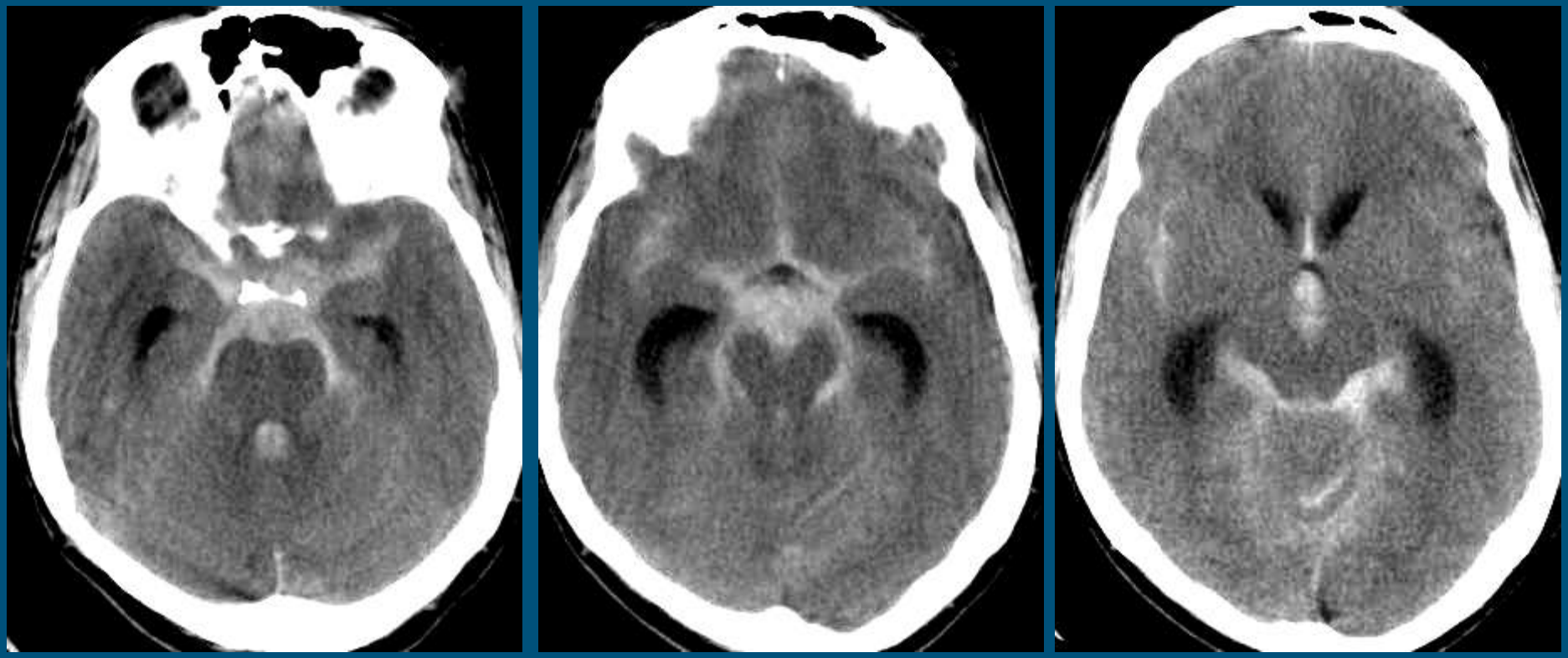

Acute subarachnoid hemorrhage

(and intraventricular)

Subdural vs. Epidural Hematoma

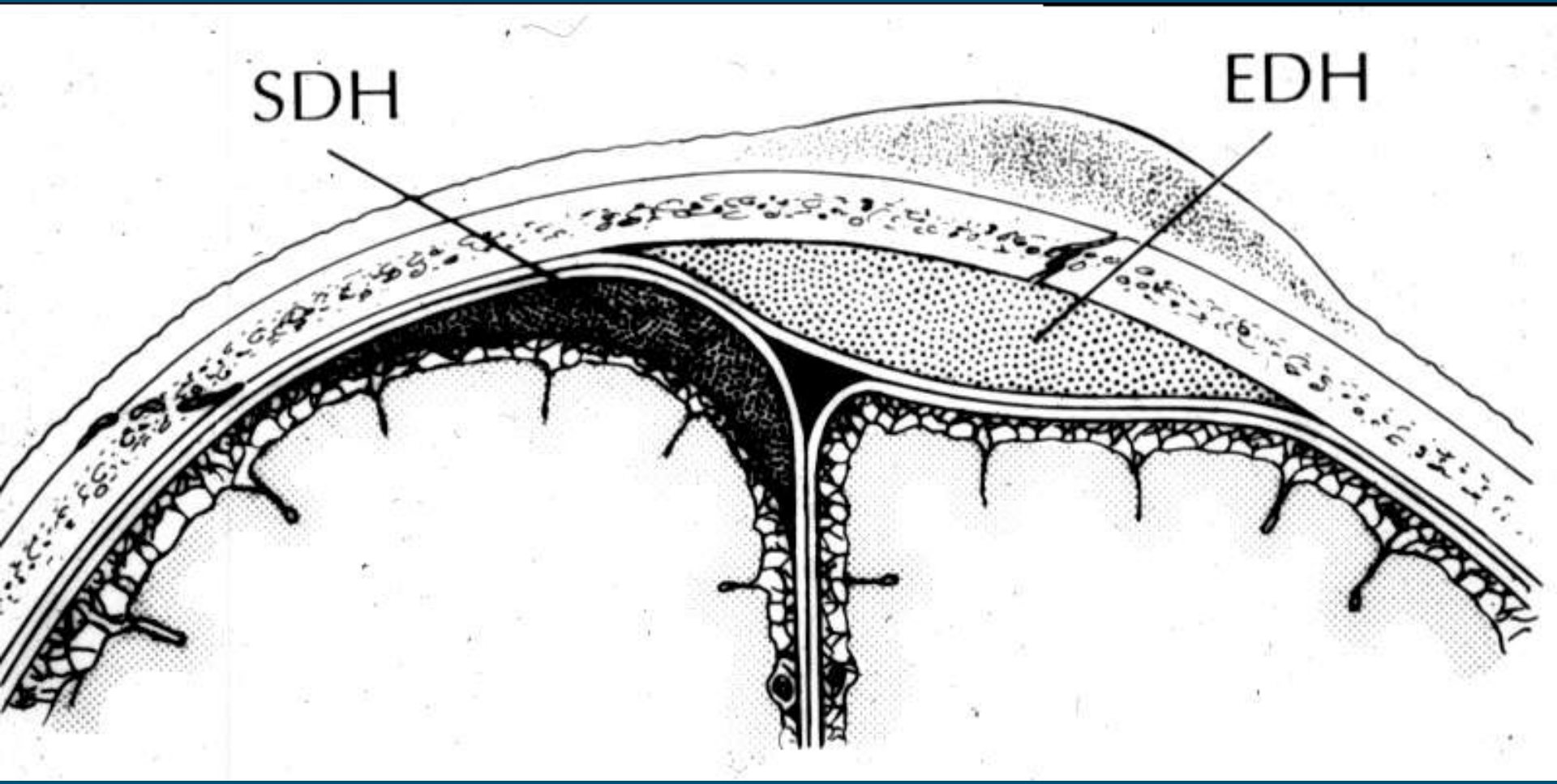

Cerebral Hemorrhage

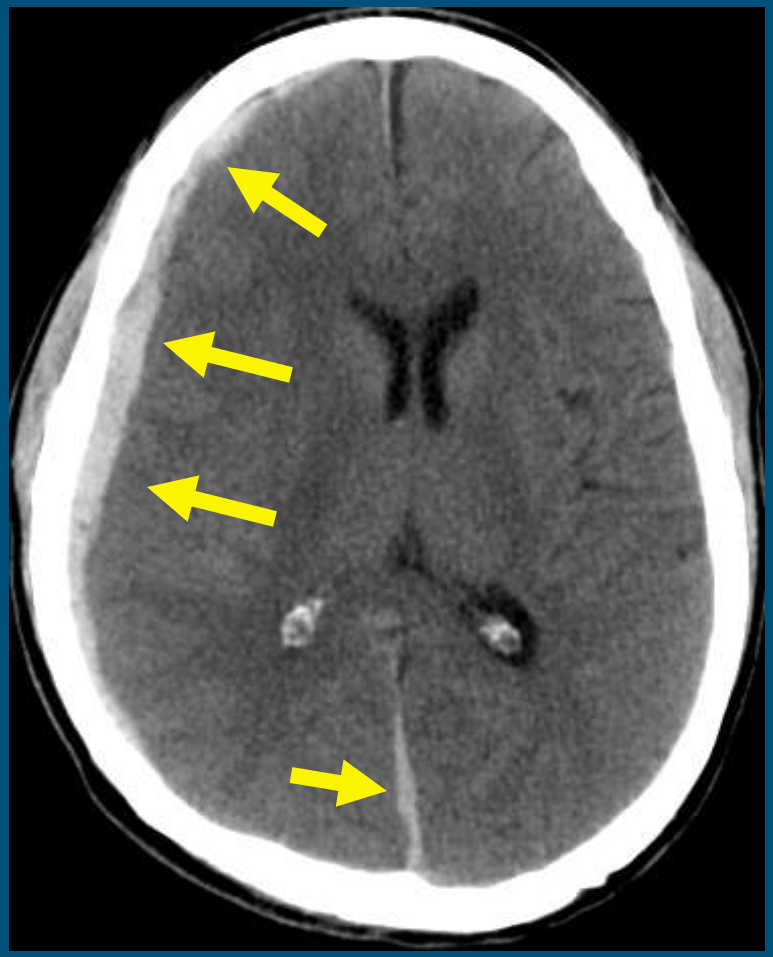

Acute subdural hematoma

Cerebral Hemorrhage

Acute epidural hematoma

Subdural vs. Epidural Hematoma

Subdural:

- Follows inner layer of dura
  - "Rounds the bend" to follow falx or tentorium
  - Not affected by sutures of skull
- Tendency for crescentic shapes
- More mass effect than expected for their size
- Typical source of SDH: cortical vein

Epidural:

- Follows outer layer of dura (periosteum)
  - Crosses falx or tentorium
  - Limited by sutures of skull (typically)
- Tendency for lentiform shapes
- Typical source of EDH:
  - skull fracture with arterial or sinus laceration

*

Cerebral Hemorrhage

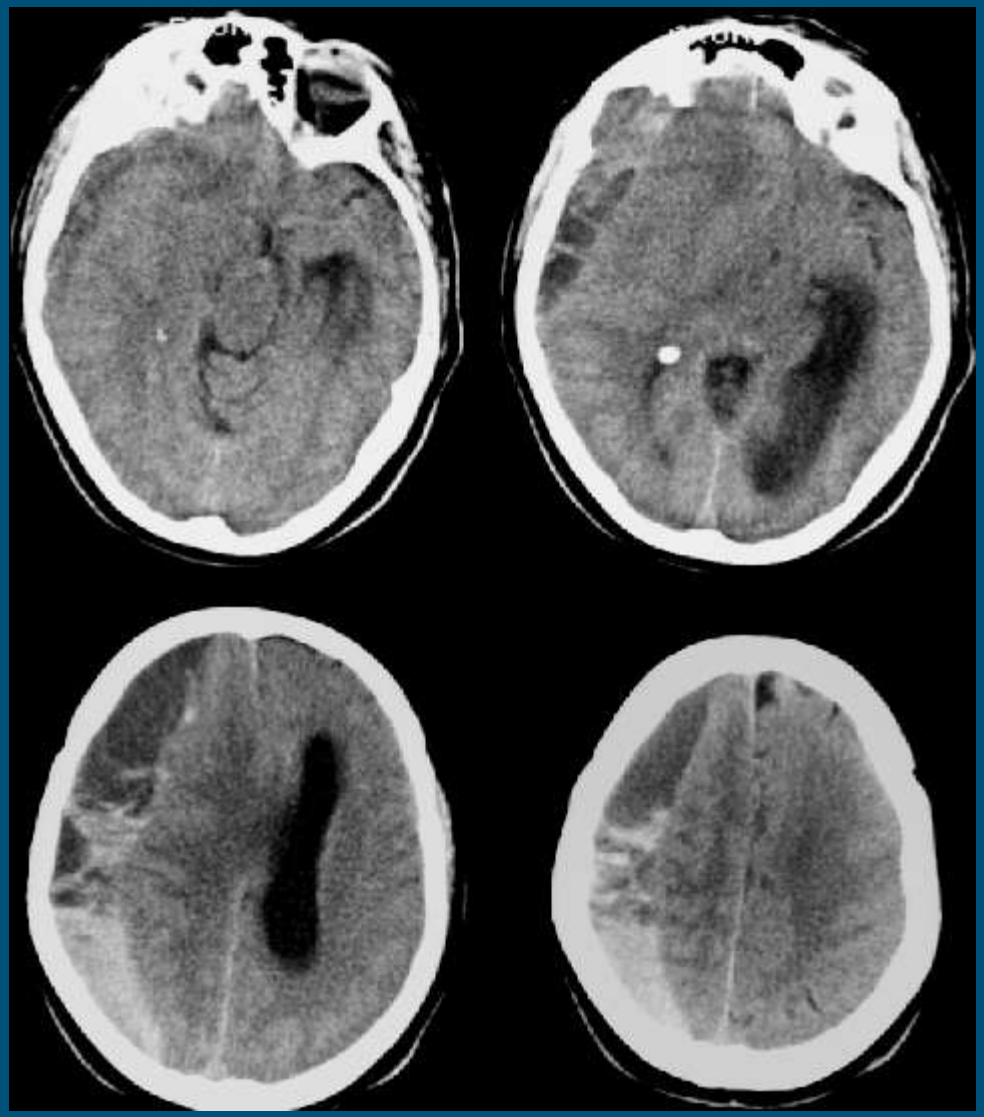

Mixed acute/chronic subdural hematoma

Cerebral Hemorrhage

Hematocrit level!

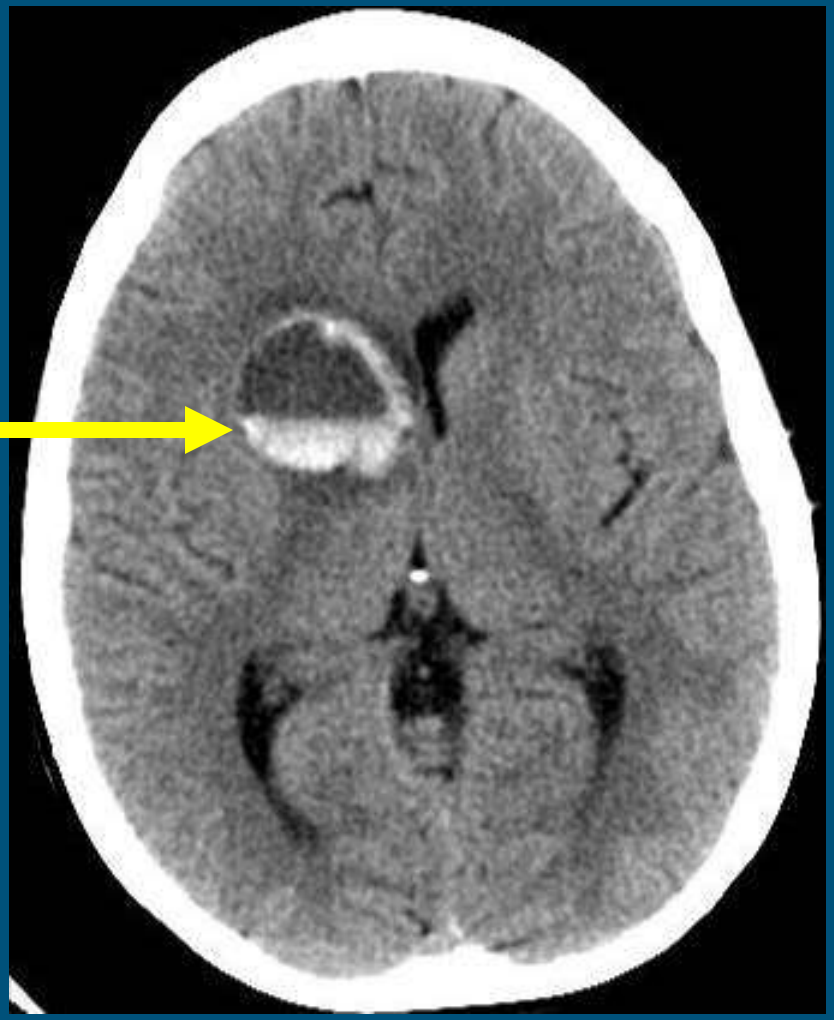

MRI of Hemorrhage

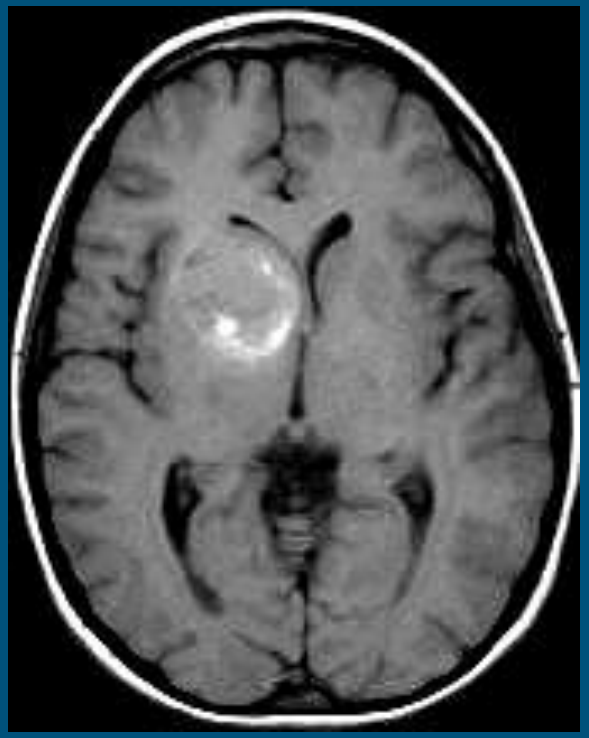

T1

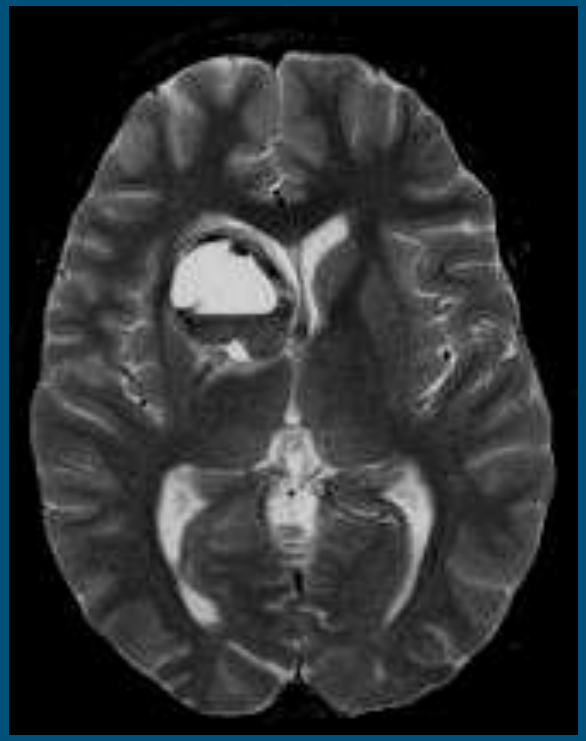

T2

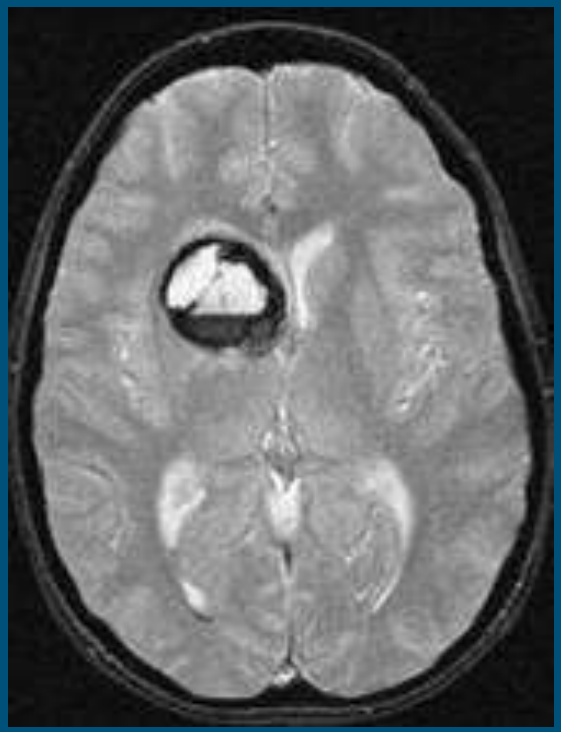

T2*

MR appearance of hematomas depends on image type.

Magnetic properties change over time (Hgb breakdown products), allowing approximate dating

Brain Imaging: “The Big 10”

- Infarction
- Hemorrhage
- Infection
- Tumor
- Trauma
- Dementia
- MS
- Epilepsy
- Cranial neuropathy
- Orbits / Ophtho dx

Infection

- Meningitis
- Encephalitis
- Cerebritis and parenchymal abscess
- Empyema (subdural/epidural)

Meningitis

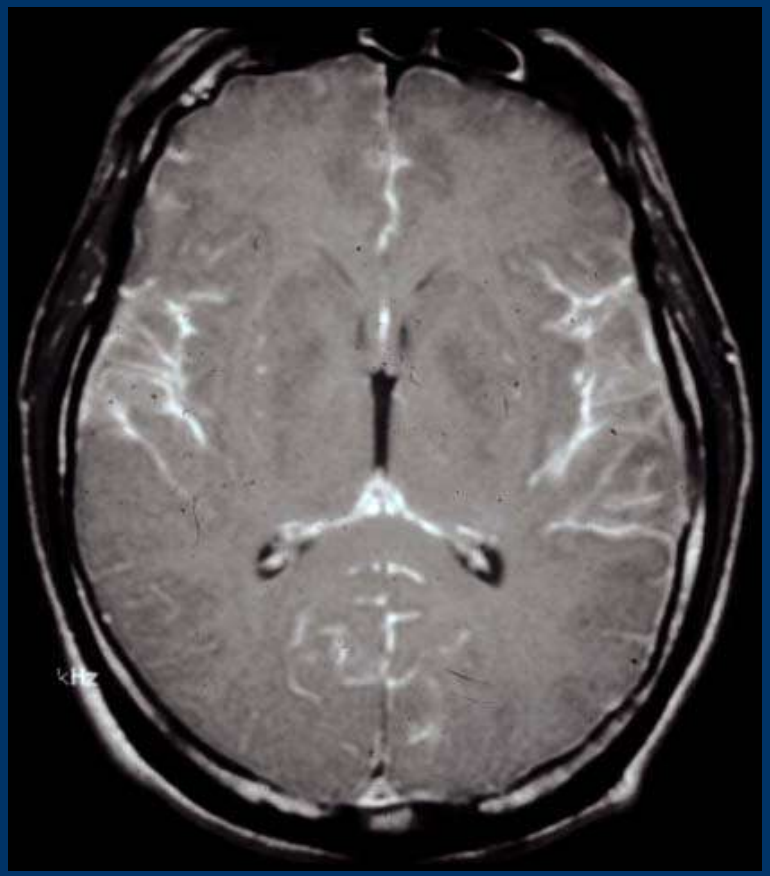

Leptomeningitis: pia-arachnoid

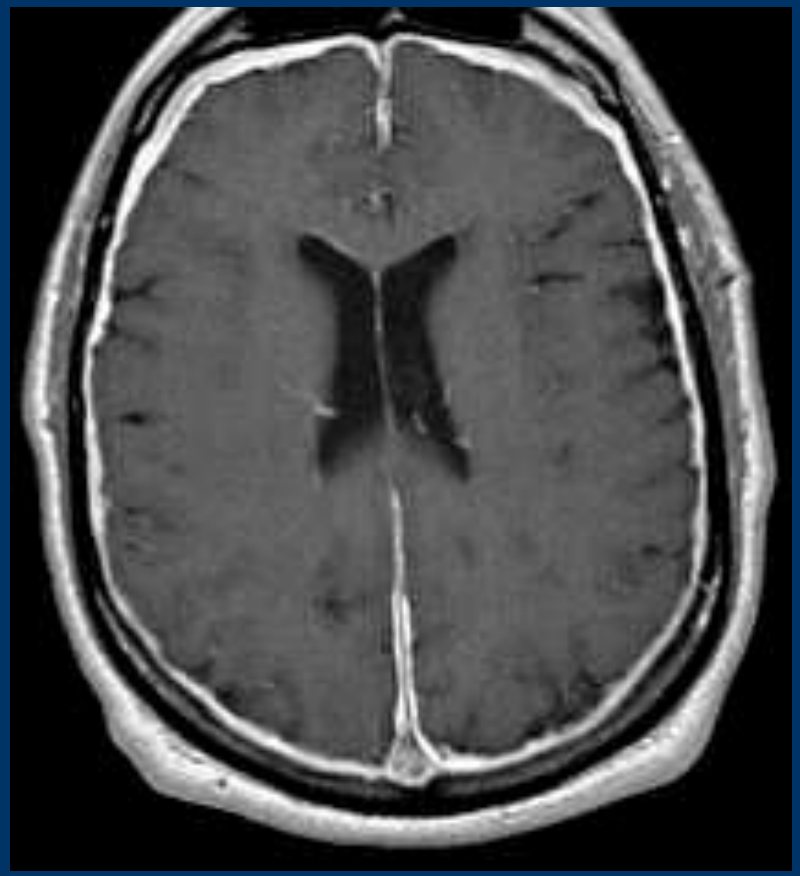

Pachymeningitis: dura

Most common imaging findings in meningitis: NONE !!

Herpes Encephalitis

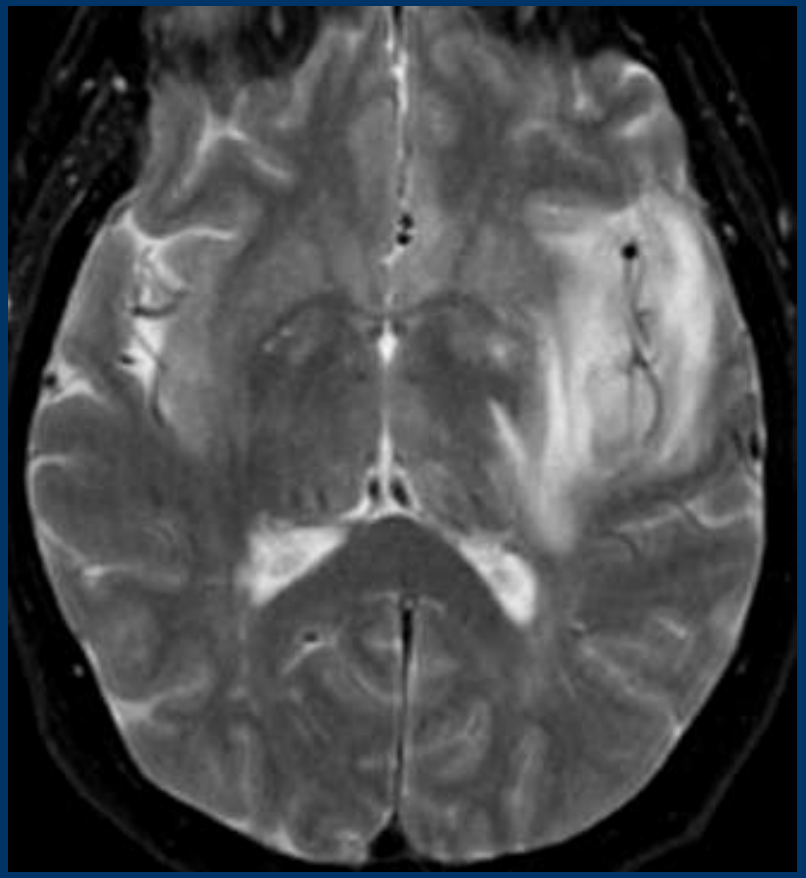

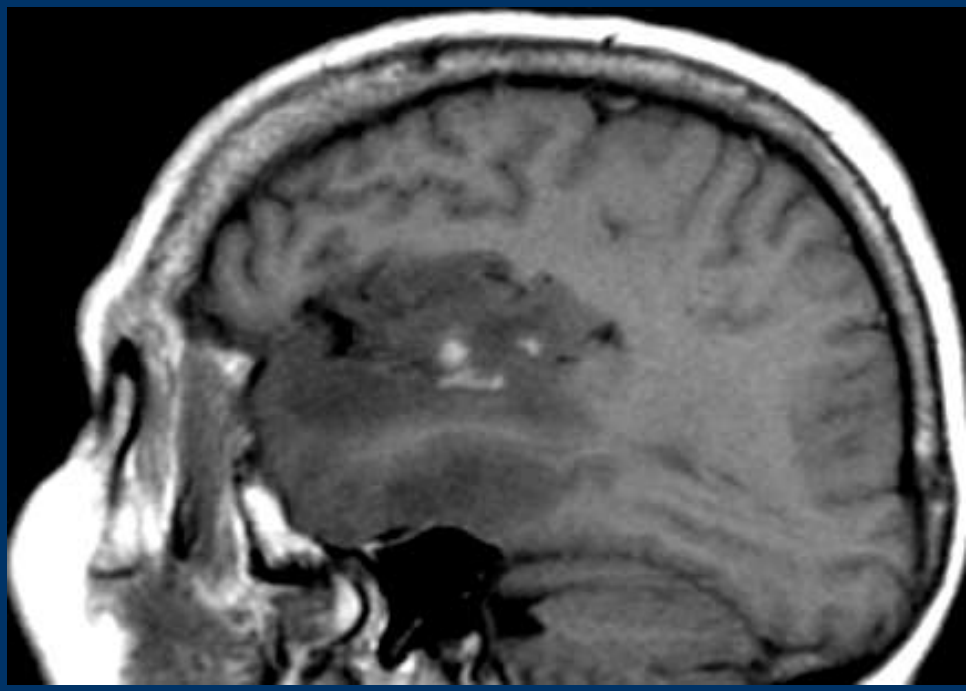

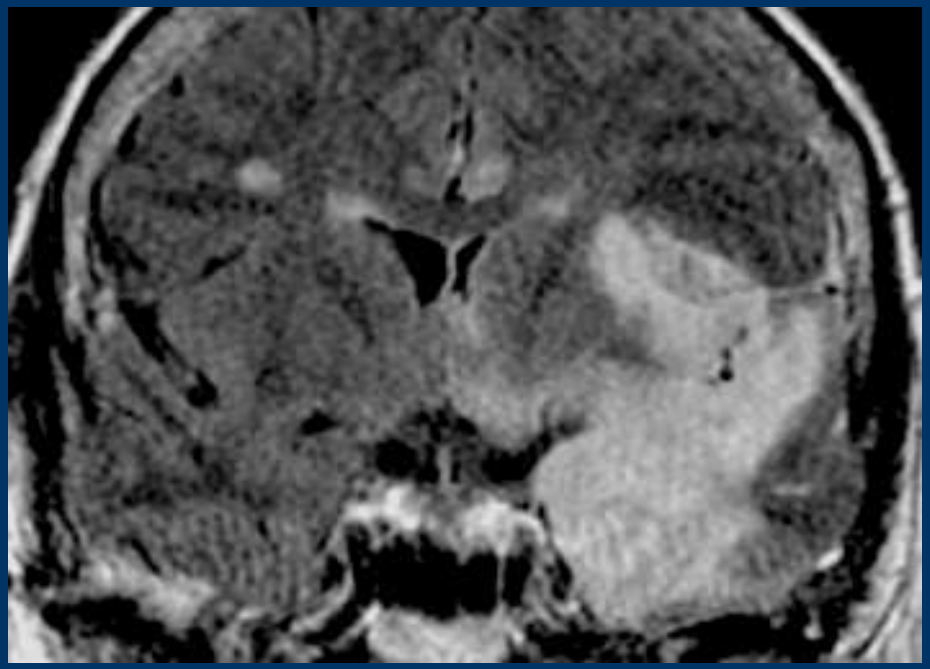

Cerebritis w/ Bacterial Abscess

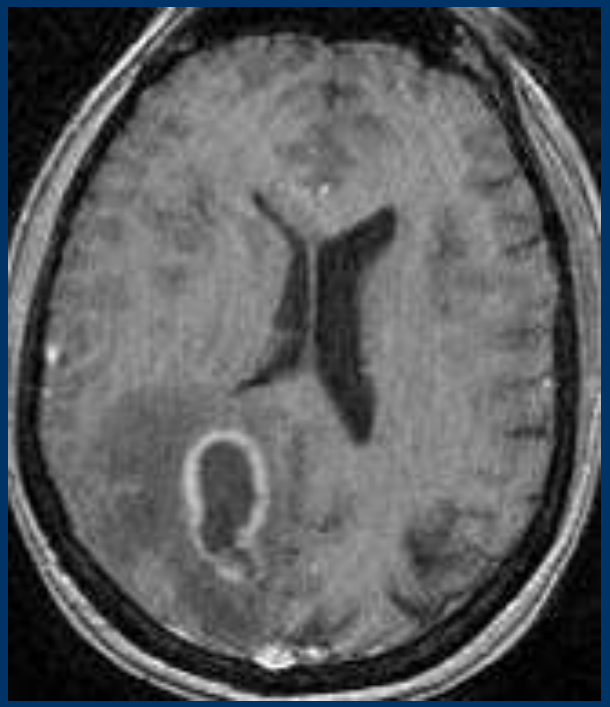

T1 + Gd

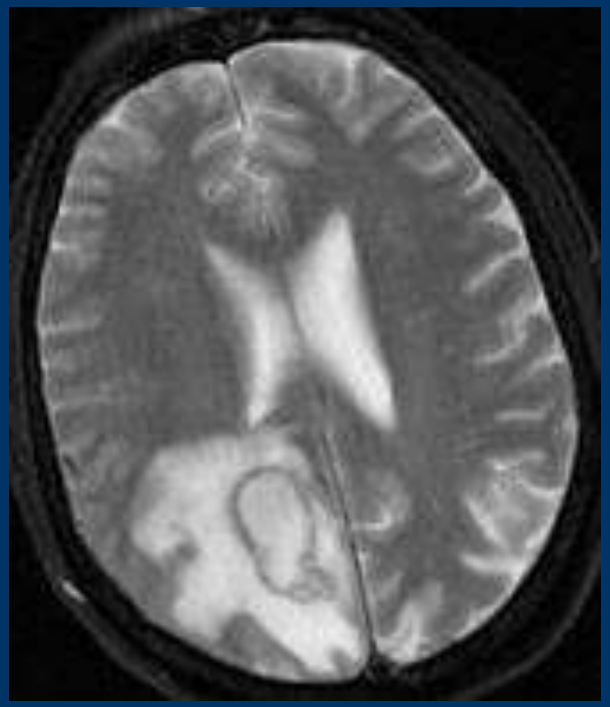

T2

Diffusion

Cerebritis w/ Subdural Empyema

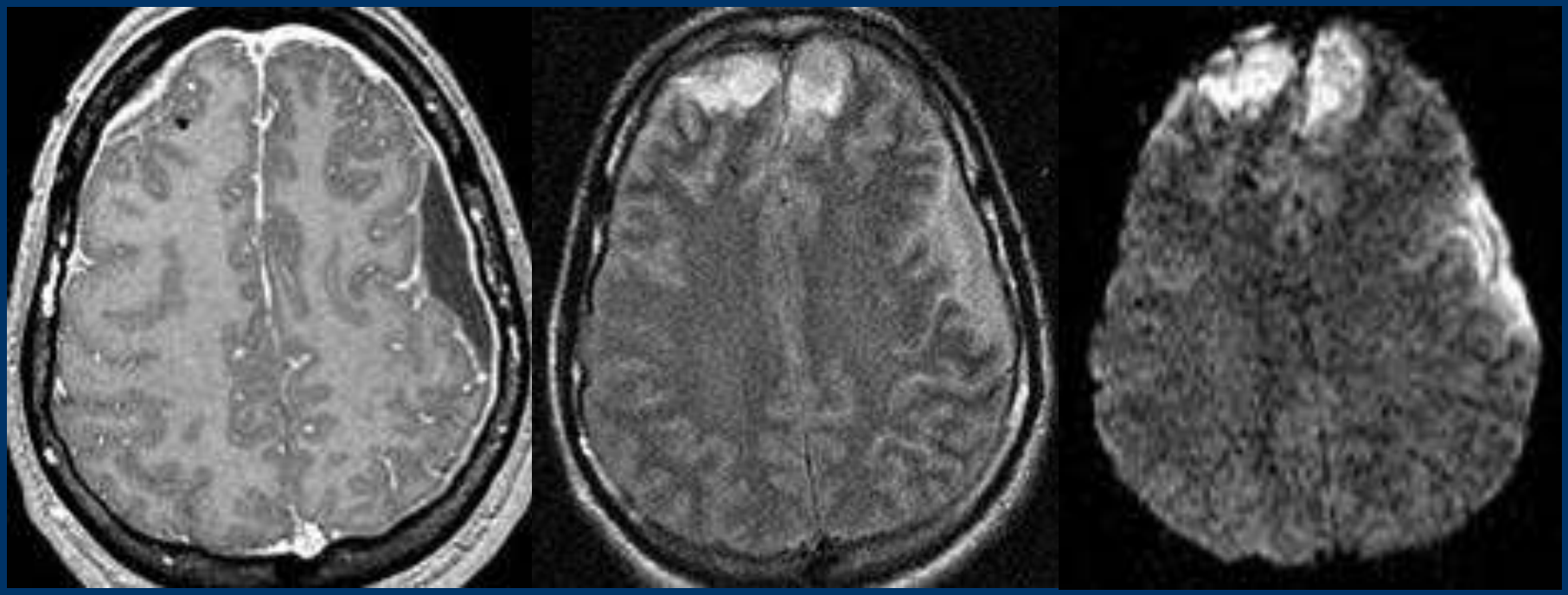

T1 + Gd | T2 FLAIR | Diffusion

Brain Imaging: “The Big 10”

- Infarction
- Hemorrhage
- Infection
- Tumor
- Trauma
- Dementia
- MS
- Epilepsy
- Cranial neuropathy
- Orbits / Ophtho dx

Brain Tumor Imaging

Diagnosis

- Location: Intra- / Extra-axial, Supra- / Infra-tentorial, Grey / white matter, etc.
- Single or multiple?
- Tumor or tumor-like alternatives?
- Histology: Type and grade?

Treatment Planning

- Surgery, radiation, chemo tx
- Functional MRI for eloquent brain mapping
- 3D scans to guide surgery, radiation

Follow-up

- Stable vs. recurrence / progression
- Complications

Intra- or Extra-axial?

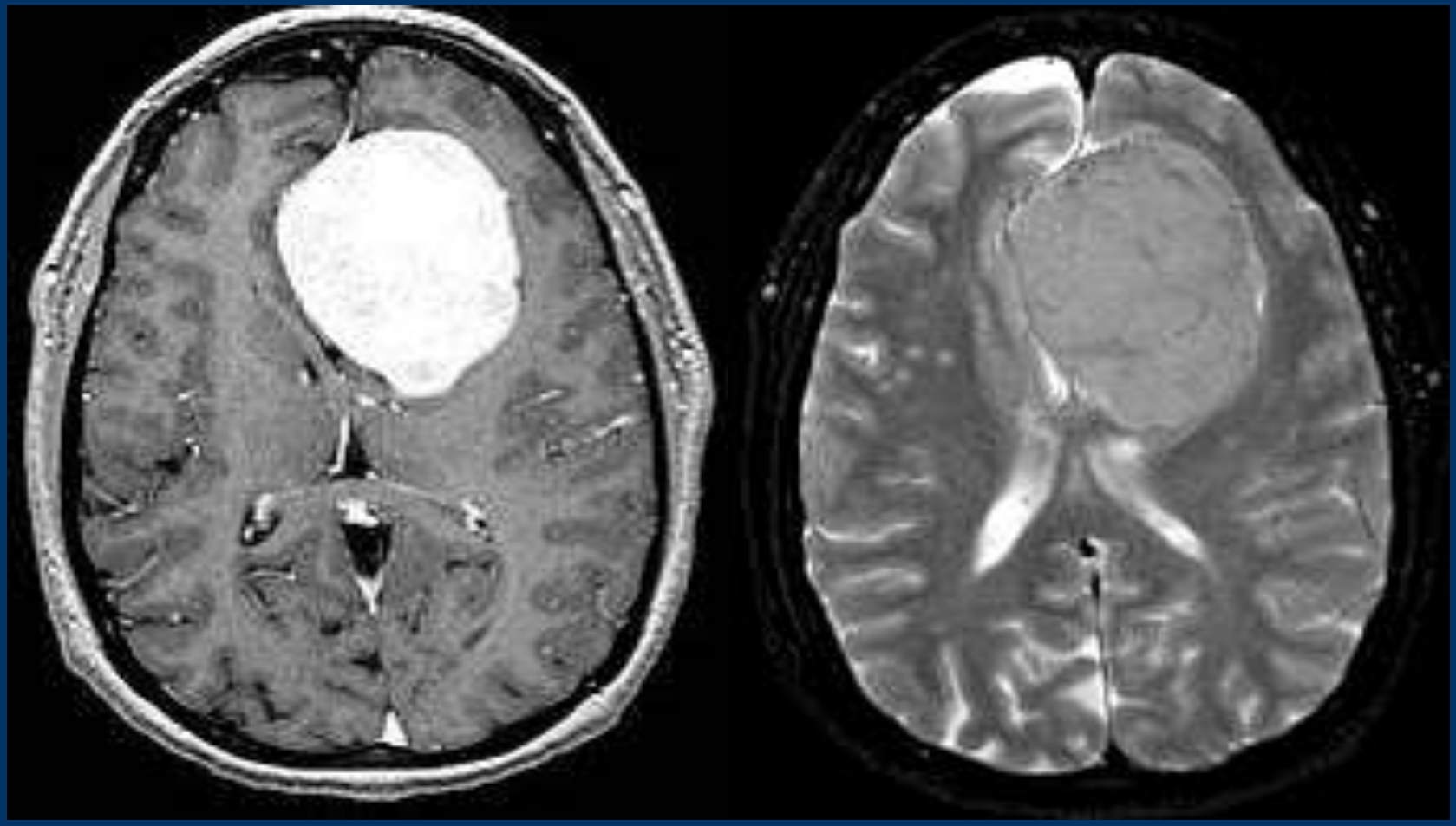

T1 + Gd

T2

Intra- or Extra-axial?

Tumor vs. Other Masses

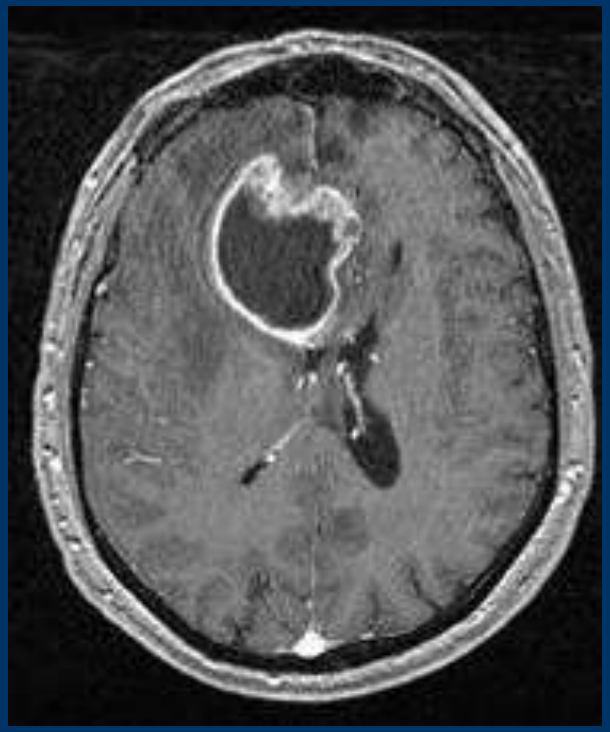

GBM

Arachnoid Cyst

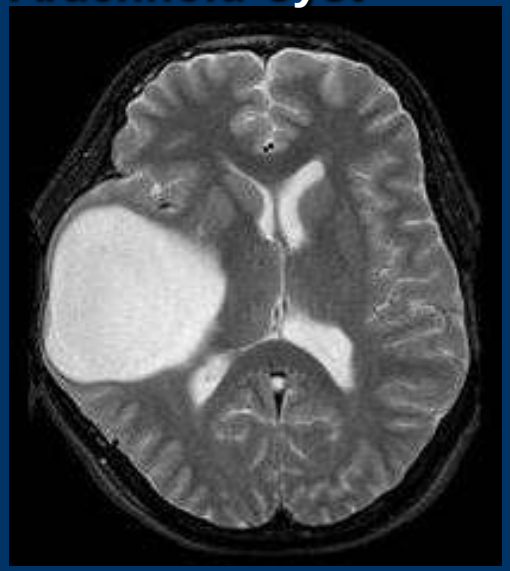

Hematoma

Abscess

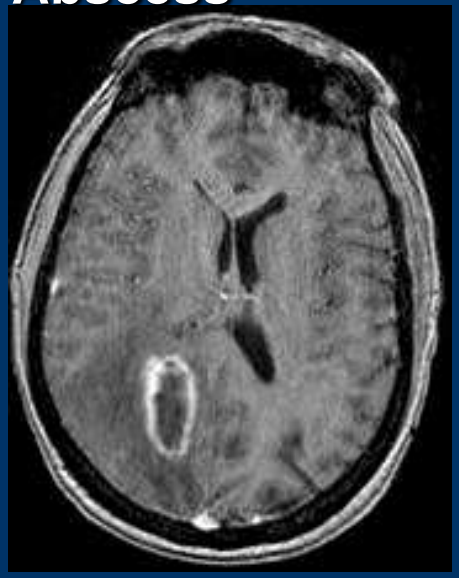

"Tumefactive" MS

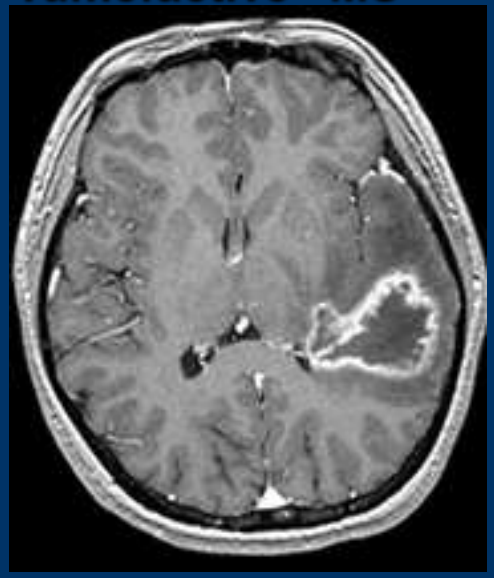

Tumor vs. Stroke

Cytotoxic Edema

Cellular swelling
Gray-white margin lost

Vasogenic Edema

Leaky capillaries
Gray matter is spared

Tumor?
Stroke?
Encephalitis?

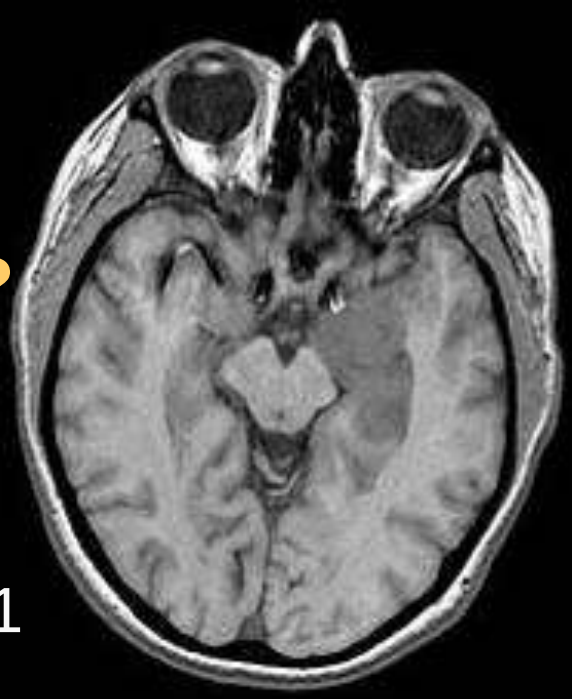

T1

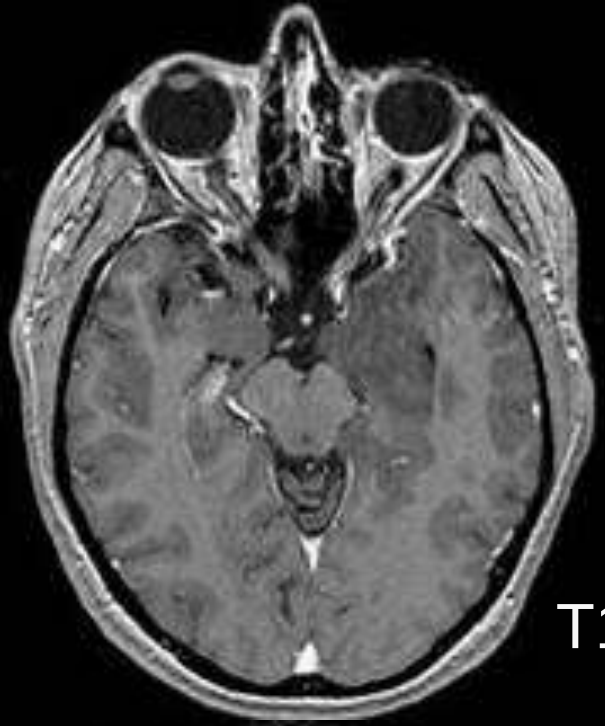

T1 + Gd

T2

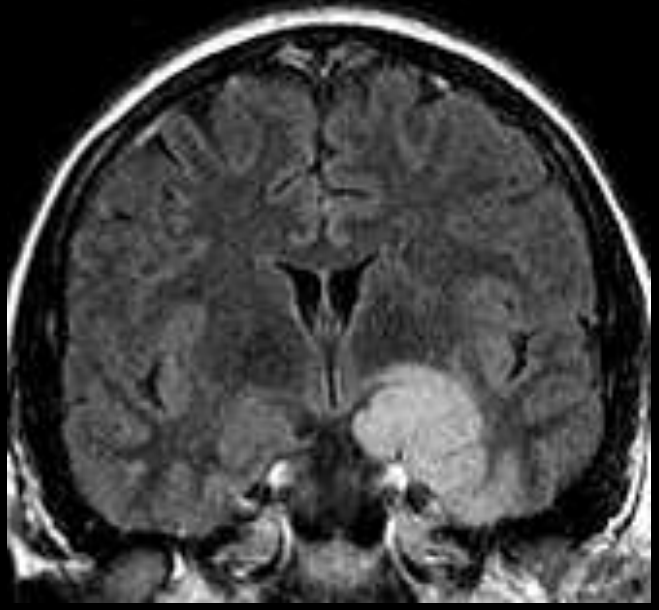

T2 FLAIR

3D Imaging for XRT or Surgical Guidance

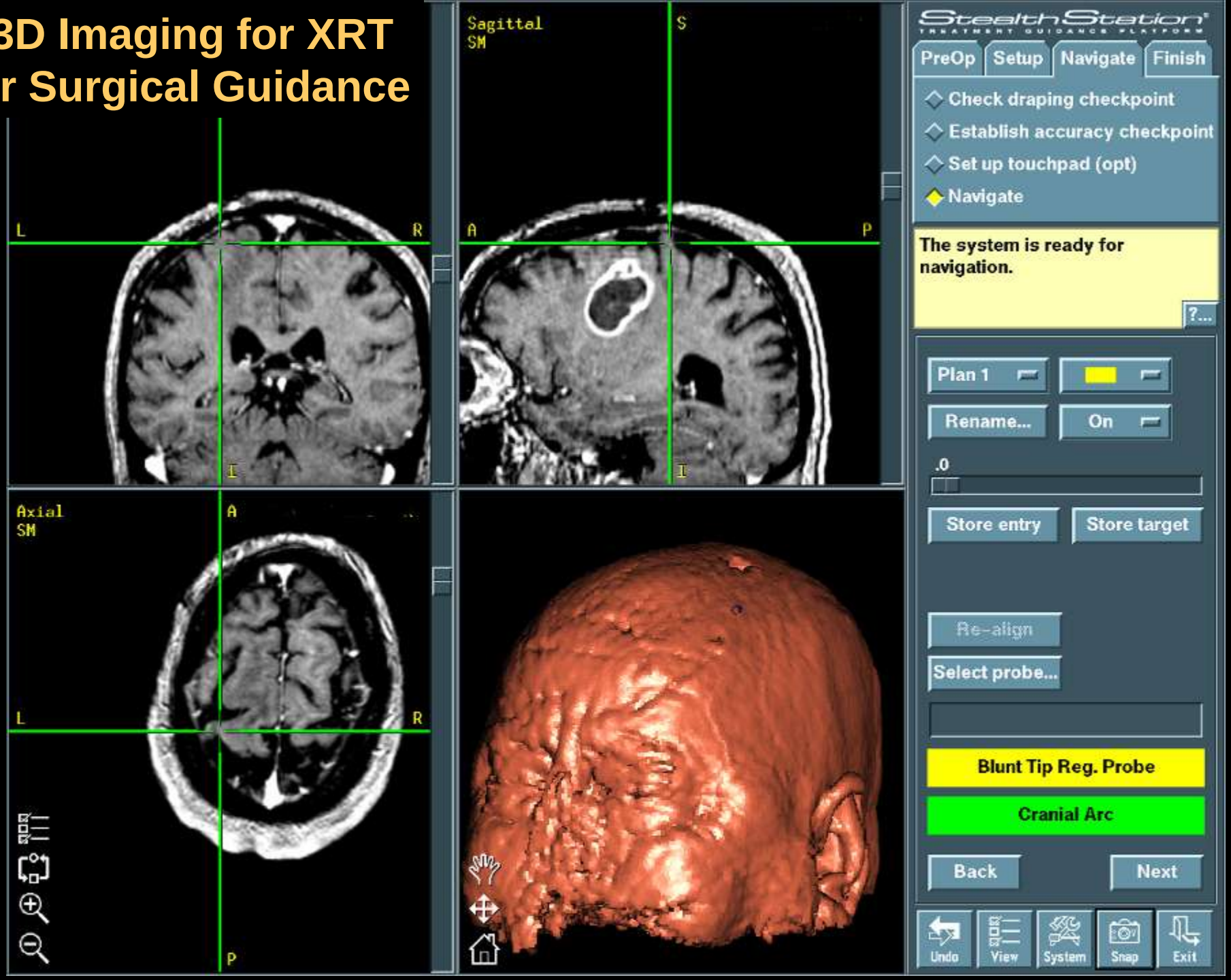

Brain Imaging: “The Big 10”

- Infarction
- Hemorrhage
- Infection
- Tumor
- Trauma
- Dementia
- MS
- Epilepsy
- Cranial neuropathy
- Orbits / Ophtho dx

Fractures: CT not MRI !

Traumatic Brain Swelling

Know your basal cisterns!

Cerebellomedullary
(Cisterna Magna)

Pontine

Cerebellopontine
angle

Traumatic Brain Swelling

Know your basal cisterns!

Suprasellar

Interpeduncular

Ambient

Quadrigeminal

Traumatic Brain Swelling

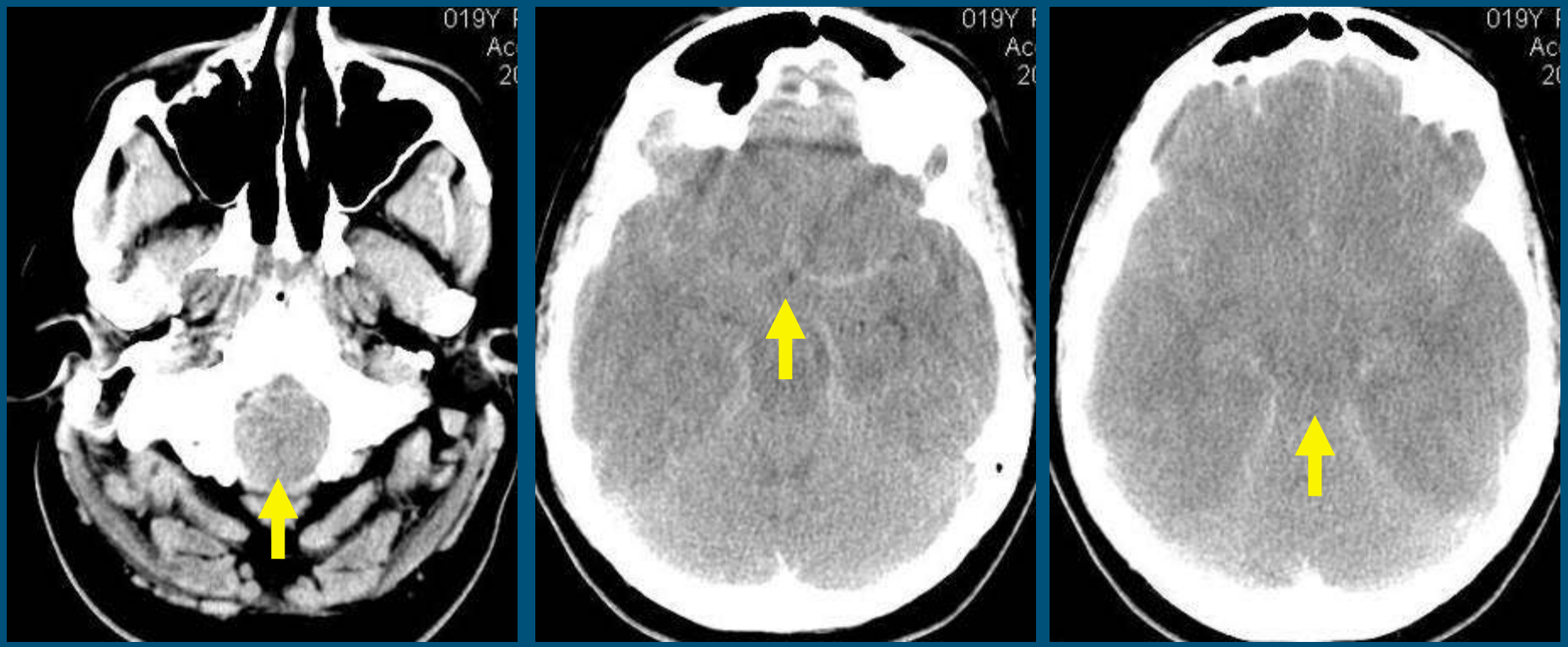

Effacement of basal cisterns

Traumatic brain swelling with downward herniation

Traumatic brain swelling

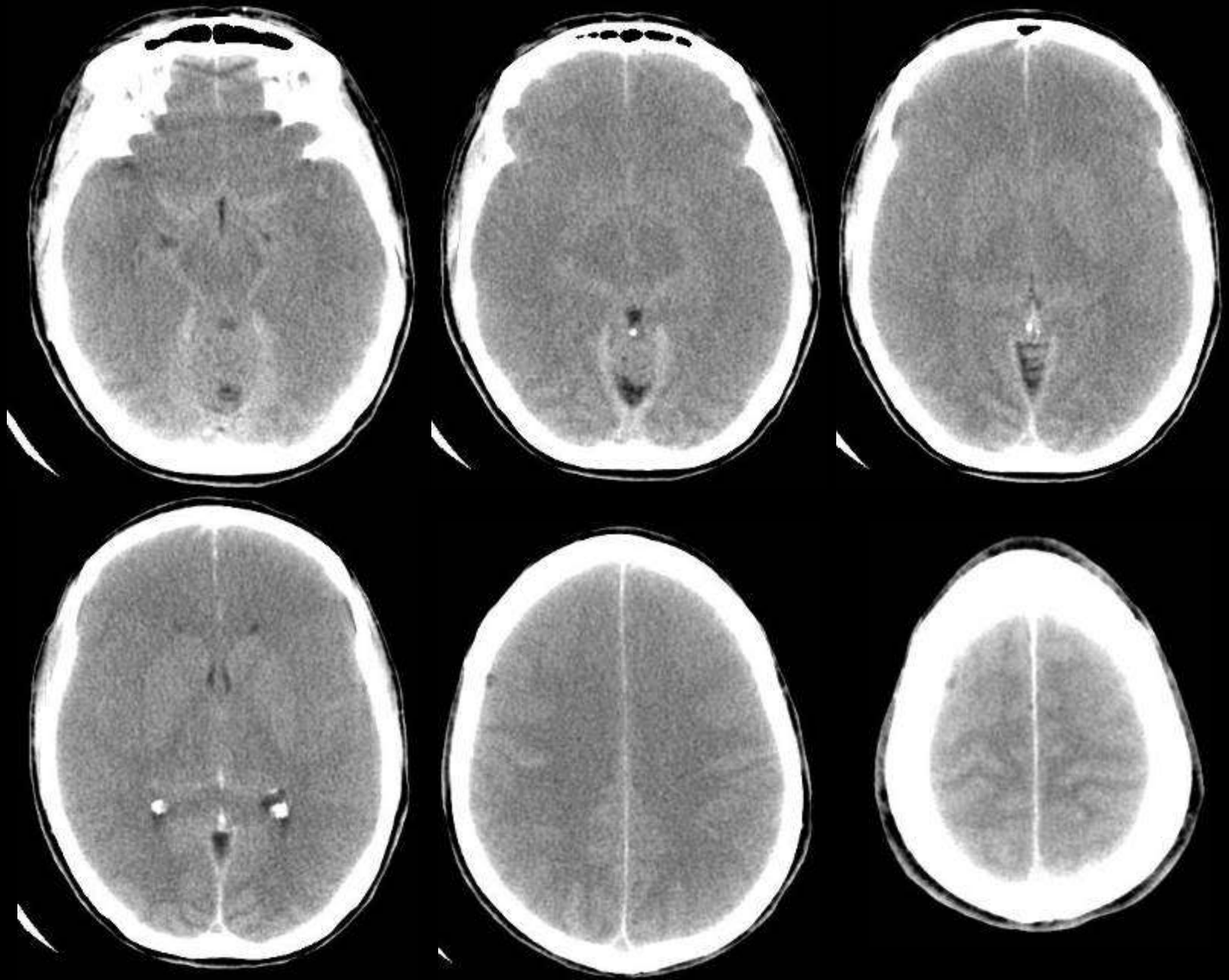

Extra-axial Hemorrhage

Subdural

Epidural

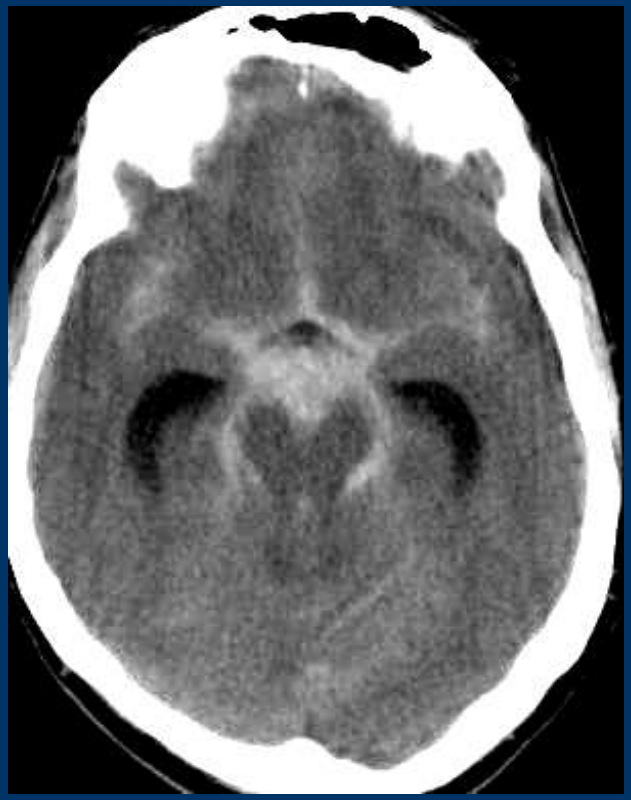

Subarachnoid

Intra-axial Hemorrhage

Hemorrhagic contusions

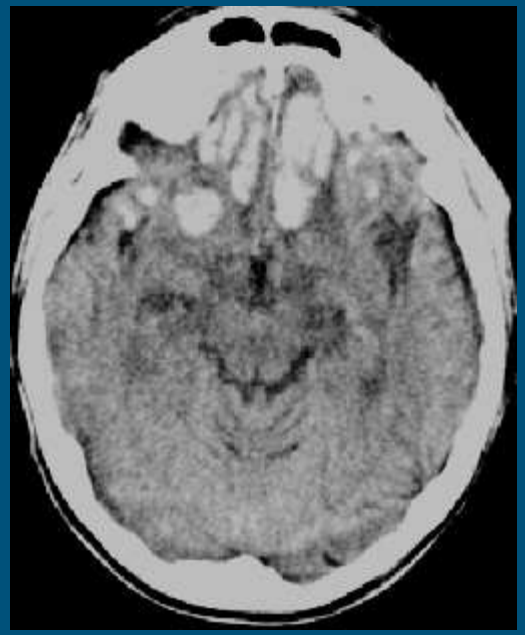

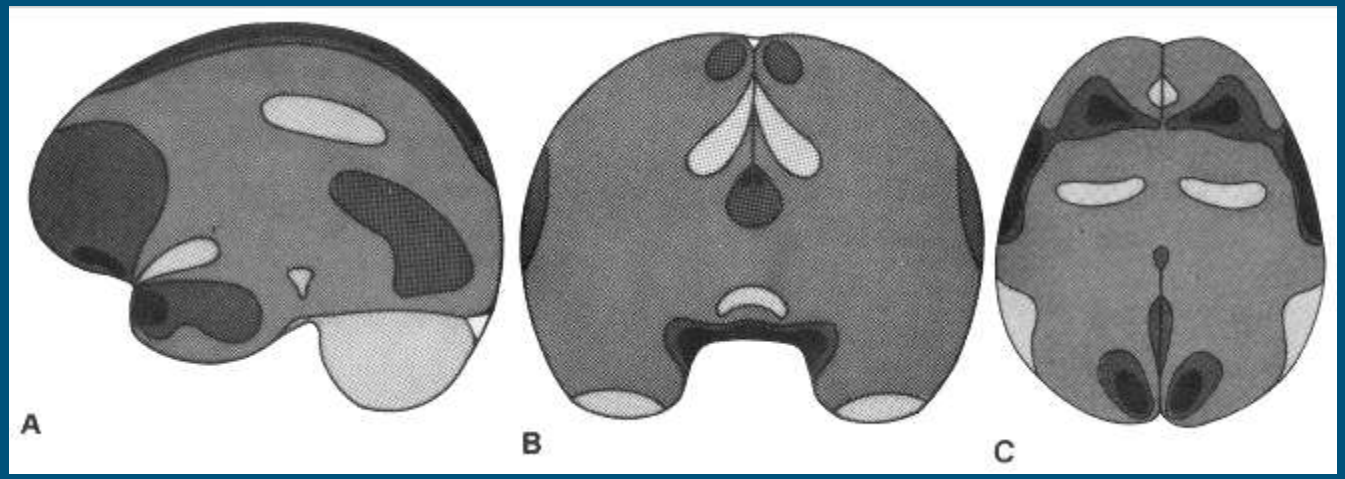

Intra-axial Hemorrhage

Hemorrhagic contusions

Mechanism

- Direct contact with skull
- Shear-strain deformation

Lesion locations

- Commonly located along inferior, lateral, and anterior frontal and temporal lobes
- Often above bony prominences (petrous pyramid, sphenoid wing, orbital roof)

Appearance of cortical contusions

- Overlying cortex, by definition, always involved (vs. DAI)
- "Salt and pepper" appearance due to intermixed hemorrhage and edema
- Non-hemorrhagic contusions often not initially seen on CT scans
- Lesions often more visible days after injury as edema and hemorrhage increase
- Acute lesions much more conspicuous on T2 or T2-FLAIR MRI

Intra-axial Hemorrhage

Diffuse Axonal (Shear) Injury (DAI)

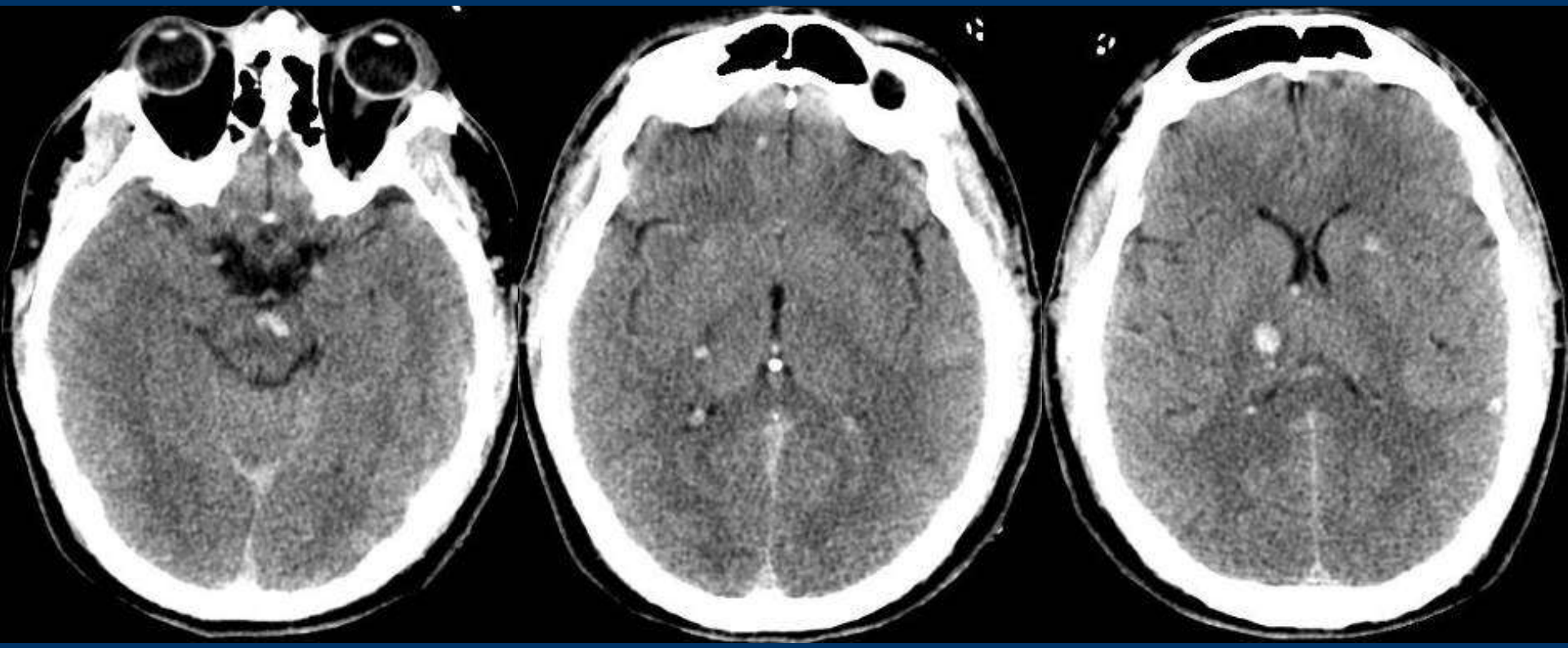

Diffuse Axonal (Shear) Injury (DAI)

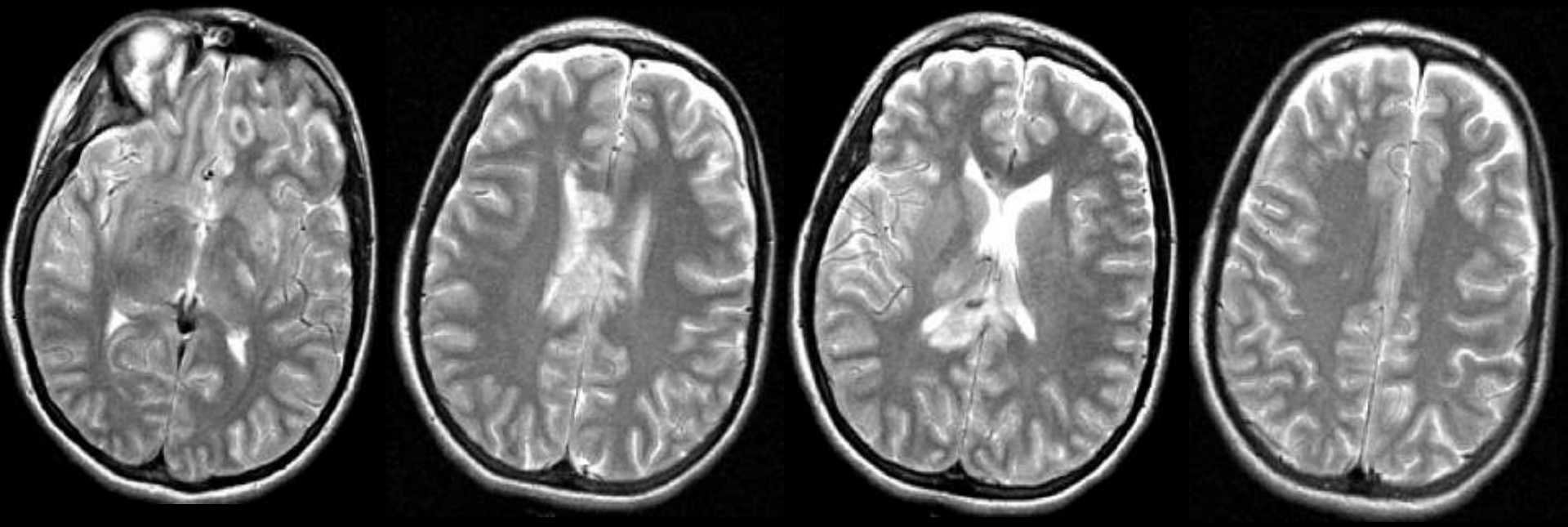

T2: Reveals non-hemorrhagic lesions occult on CT

Diffuse Axonal (Shear) Injury (DAI)

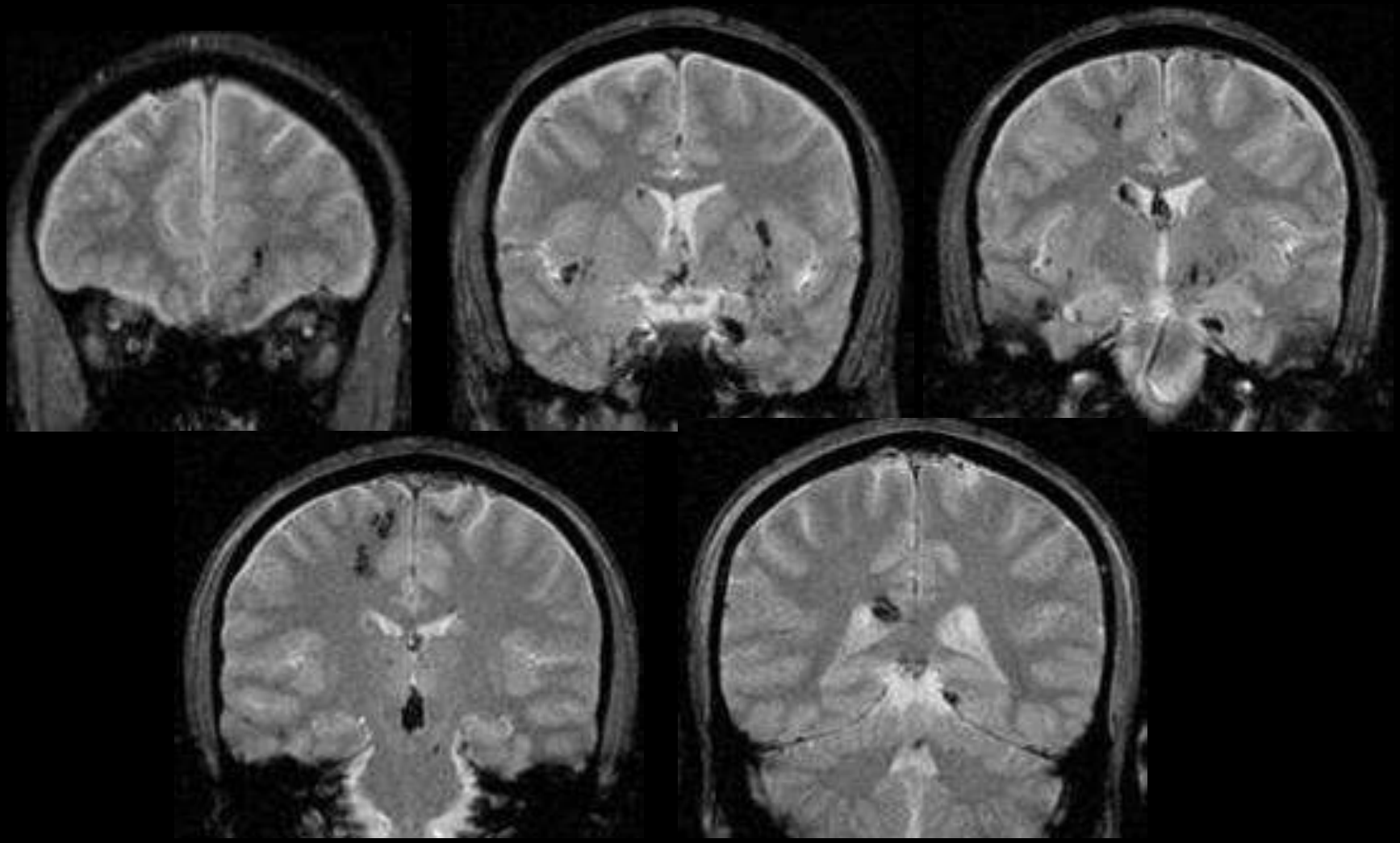

T2*: Increased sensitivity to hemorrhage

Diffuse Axonal (Shear) Injury (DAI)

- Tissues w/ differing elastic properties shear against each other, tearing axons
- Caused by rapid deceleration/rotation of head
- Locations:
  - Cerebral hemispheres near gray-white junction
  - Basal ganglia
  - Corpus callosum, especially splenium
  - Dorsal brainstem
- High morbitity & mortality – common cause of post-traumatic vegetative state
- Initial CT often normal despite poor GCS
  - Lesions often non-hemorrhagic and seen only on MRI

Brain Imaging: “The Big 10”

- Infarction
- Hemorrhage
- Infection
- Tumor
- Trauma
- Dementia
- MS
- Epilepsy
- Cranial neuropathy
- Orbits / Ophtho dx

Dementia

- Primary role of imaging is to <u>exclude treatable causes, e.g.:</u>
  - Hydrocephalus
  - Subdural hematoma
  - Neoplasm

Dementia

Irreversible dementias (imaging non-specific):

- Alzheimer's disease
- Multi-infarct dementia
- Dementias associated with Parkinson's disease and similar disorders
- AIDS dementia complex

Alzheimer’s: Temporal-Parietal Lobe Atrophy (Late)

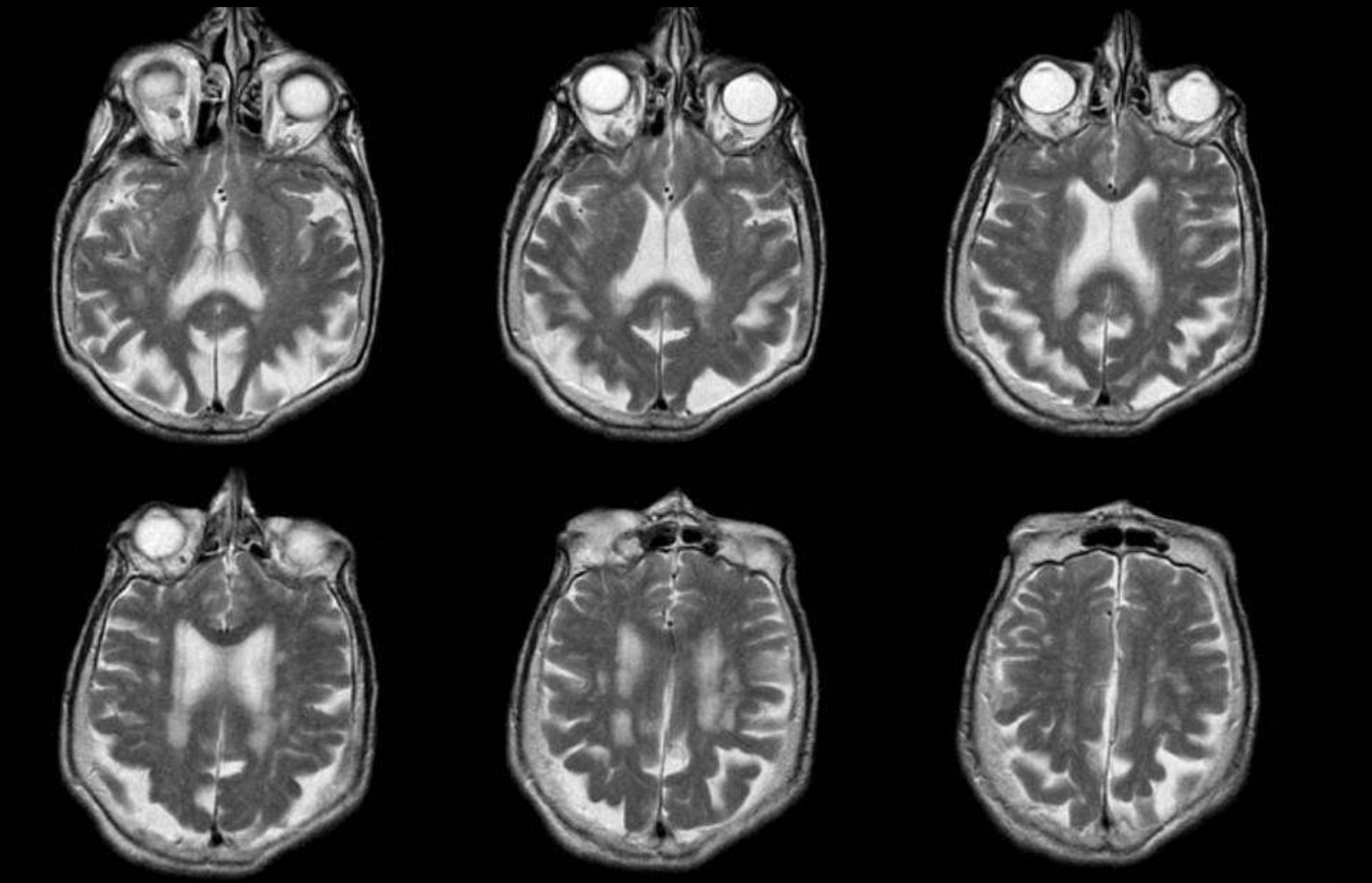

Brain Imaging: “The Big 10”

- Infarction
- Hemorrhage
- Infection
- Tumor
- Trauma
- Dementia
- MS
- Epilepsy
- Cranial neuropathy
- Orbits / Ophtho dx

Multiple Sclerosis (MS) Imaging

- MRI is the imaging study of choice
- Help establish "dissemination of lesions in time and space"
- Estimate disease burden
- Identify acute (inflammatory) vs. chronic lesions (enhancement = active inflammation)

MS

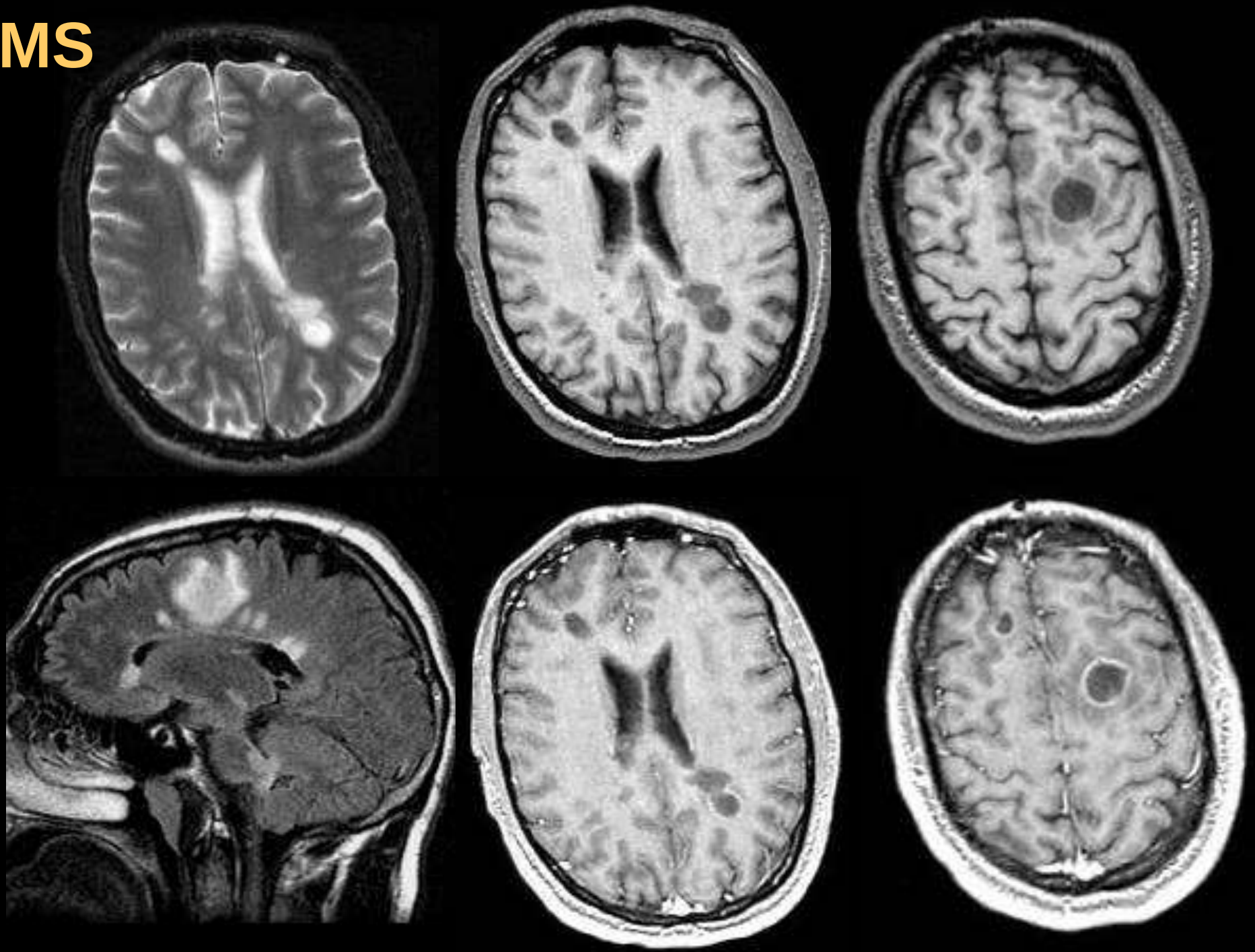

Tumefactive MS

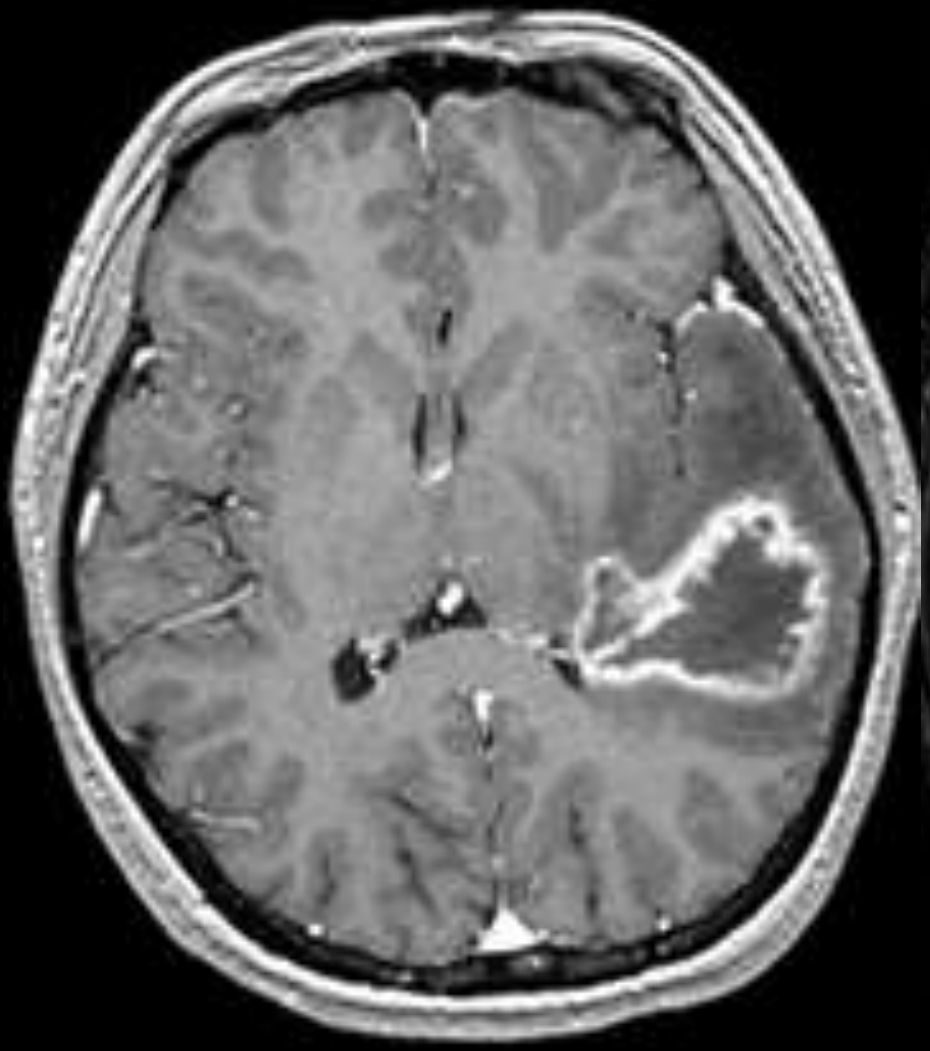

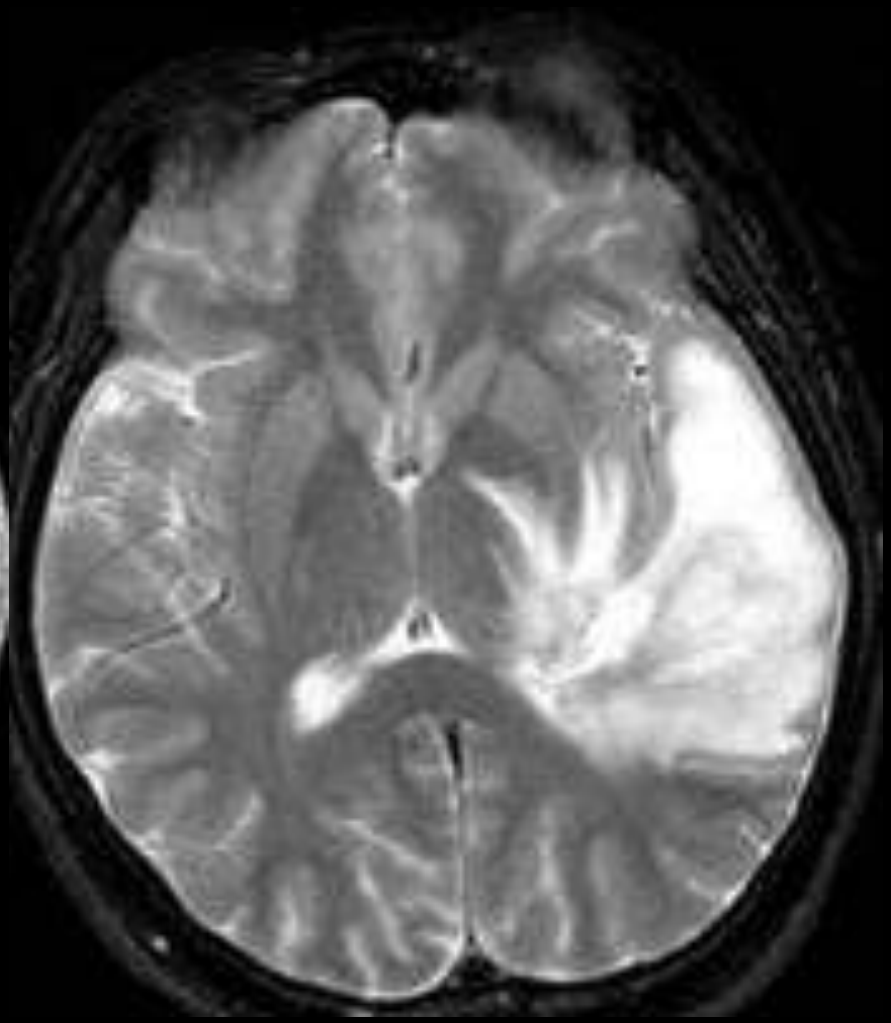

Brain Imaging: “The Big 10”

- Infarction
- Hemorrhage
- Infection
- Tumor
- Trauma
- Dementia
- MS
- Epilepsy
- Cranial neuropathy
- Orbits / Ophtho dx

Seizure Imaging

- MRI is the imaging study of choice
- Identify and localize offending lesion
  - New onset vs. chronic epilepsy
  - Younger vs. older patients
  - Search may be guided by EEG / clinical sx
- Preoperative planning

  e.g. language lateralization before temporal lobectomy

Congenital anomalies: Polymicrogyria

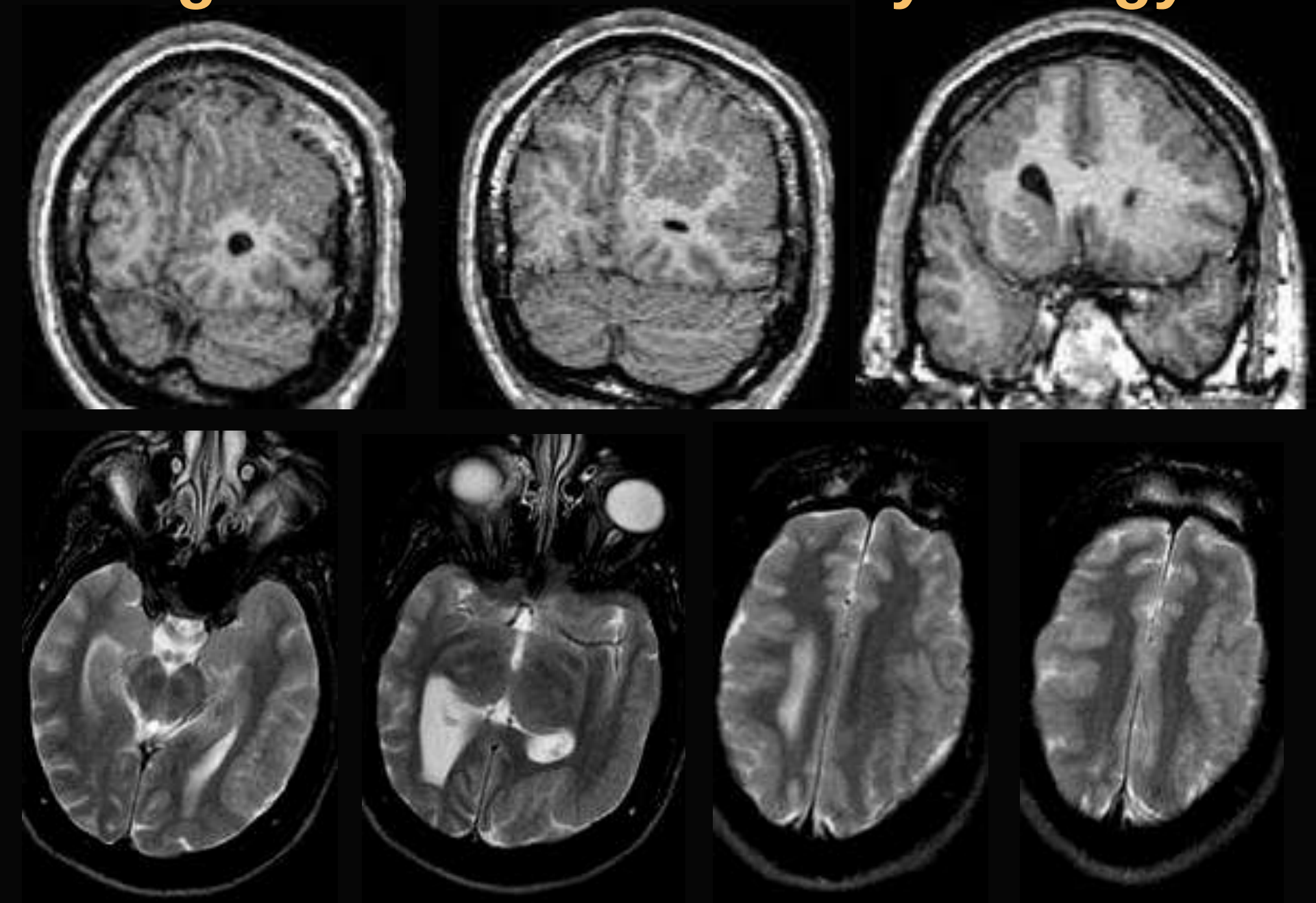

Congenital anomalies: Schizencephaly

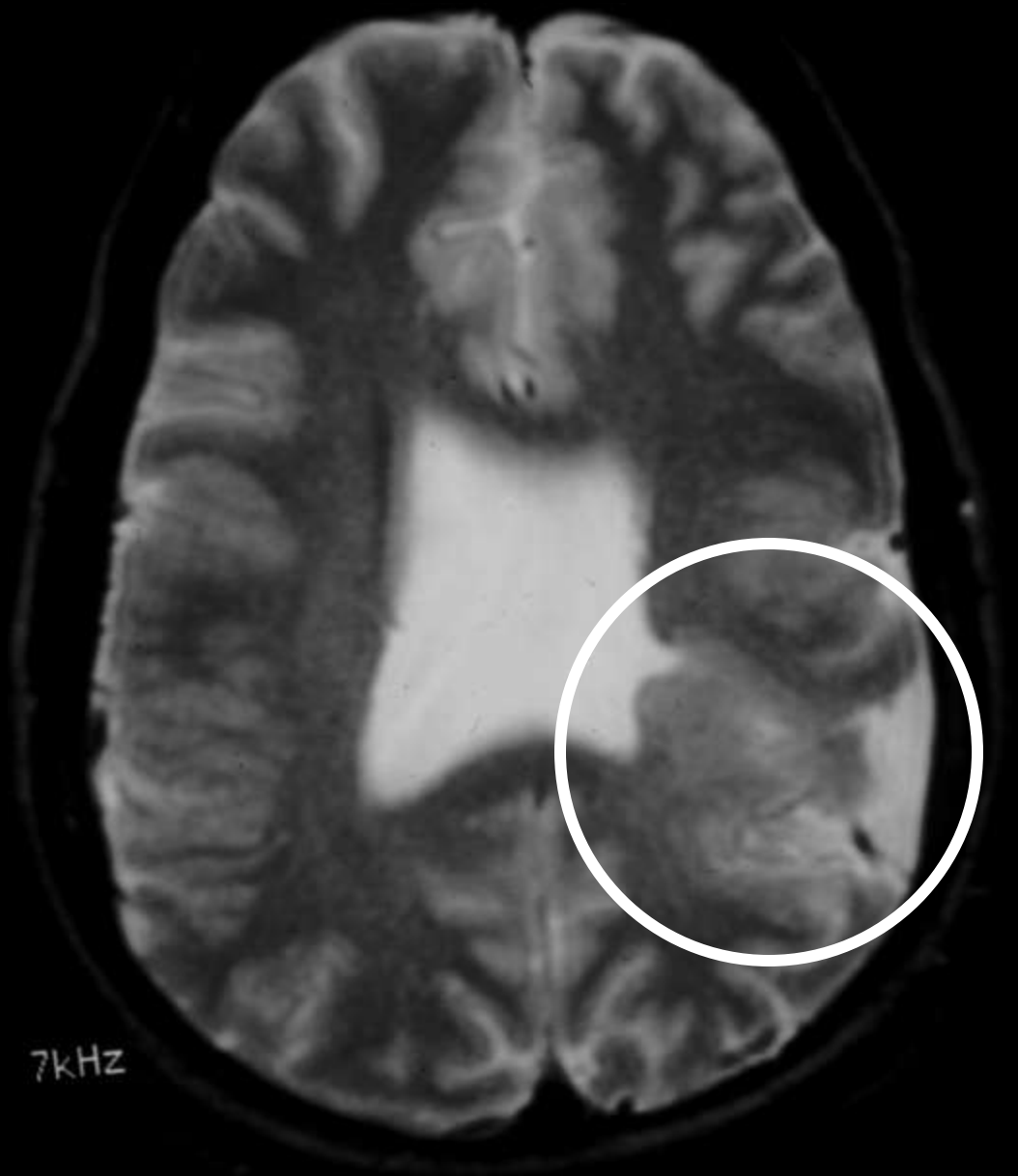

Mesial Temporal Sclerosis

Most common pathology found in medically refractory epilepsy patients

Rare under age 10 or with new seizures

Pathogenesis unknown
- Post ictal / kindling?

Pathology:
Hippocampal atrophy / gliosis

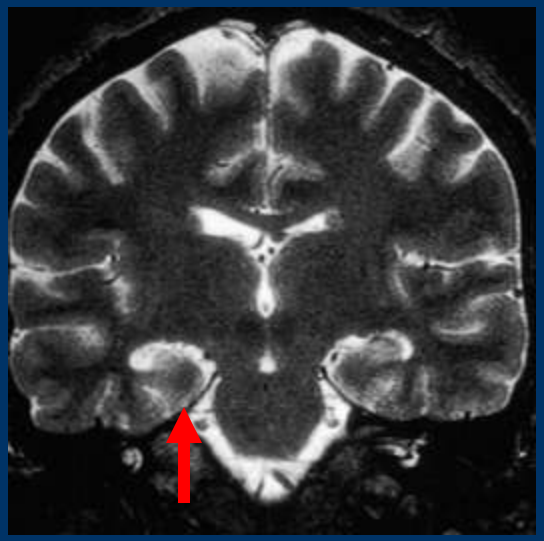

Mesial Temporal Sclerosis

- *Atrophy*
- *Loss gray-white*
- *↑T2 / FLAIR*

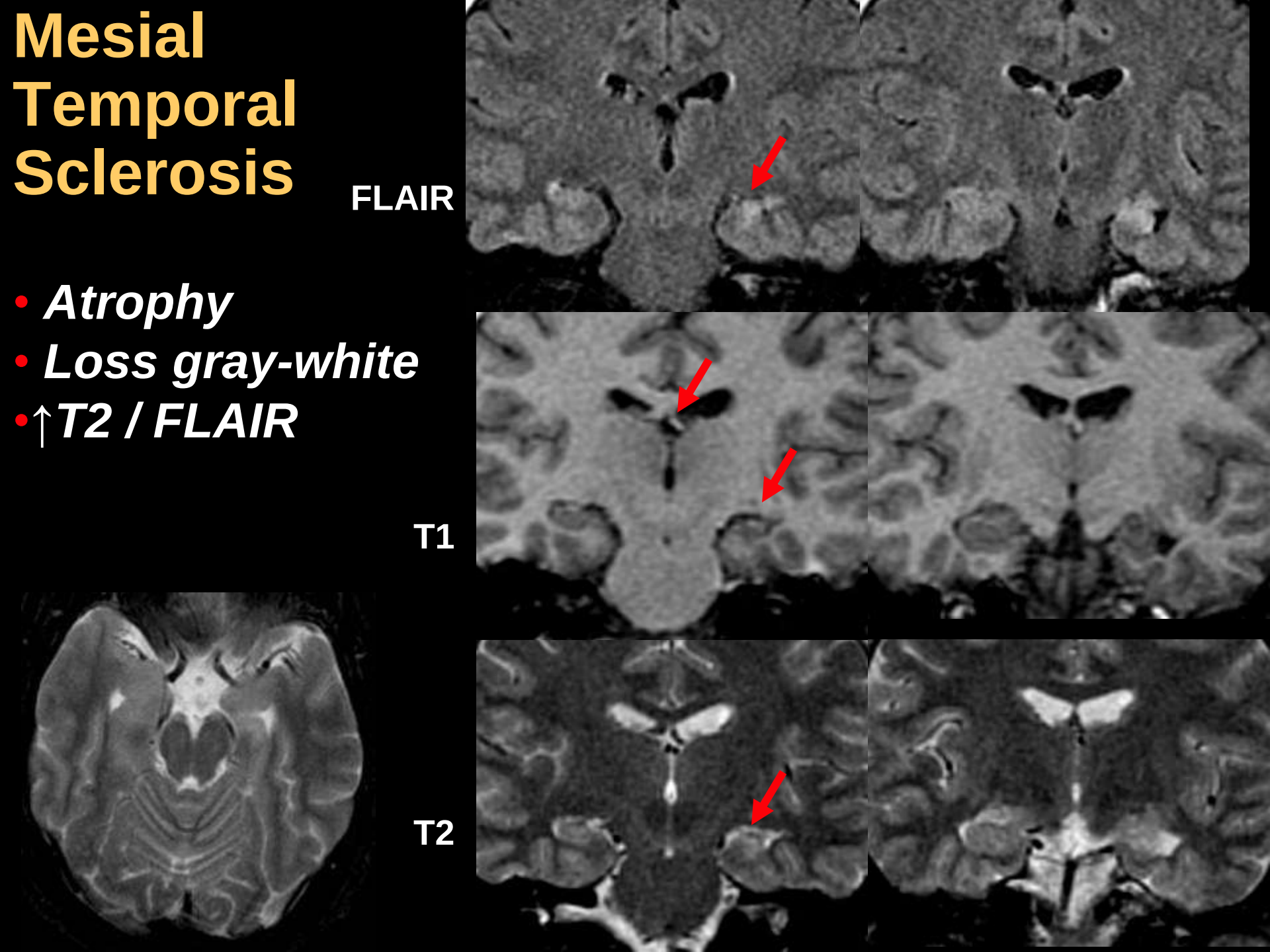

Brain Imaging: “The Big 10”

- Infarction
- Hemorrhage
- Infection
- Tumor
- Trauma
- Dementia
- MS
- Epilepsy
- Cranial neuropathy
- Orbits / Ophtho dx

Cranial Nerve Imaging

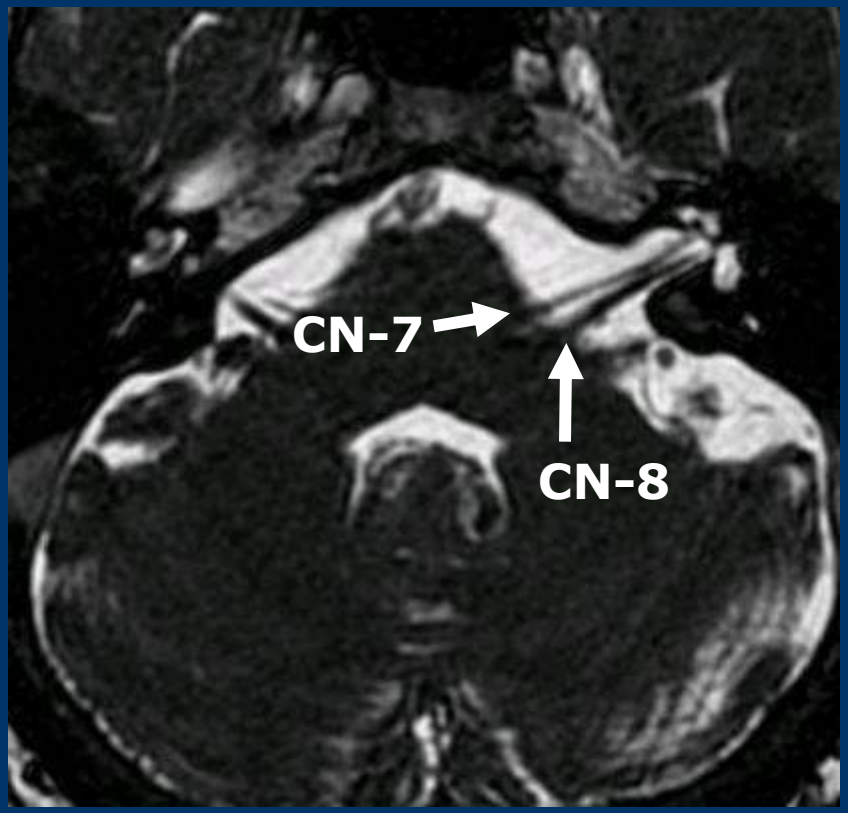

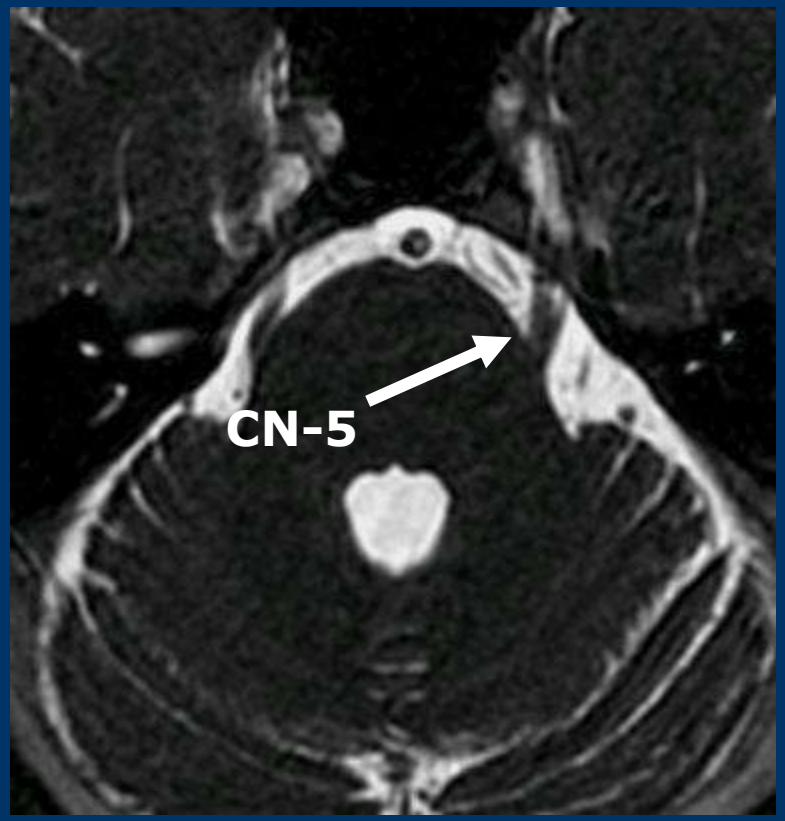

FIESTA

Vestibular Schwannoma

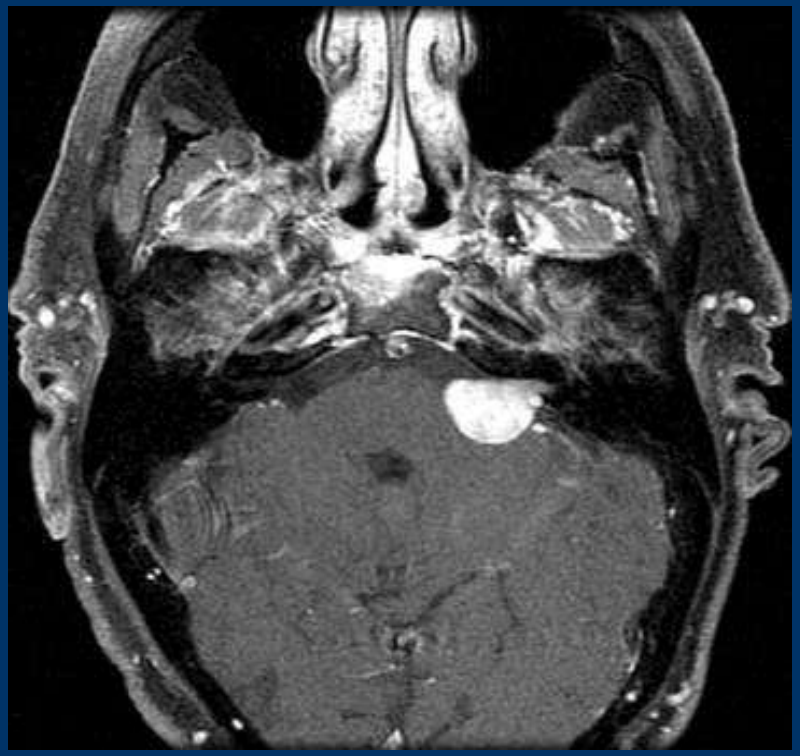

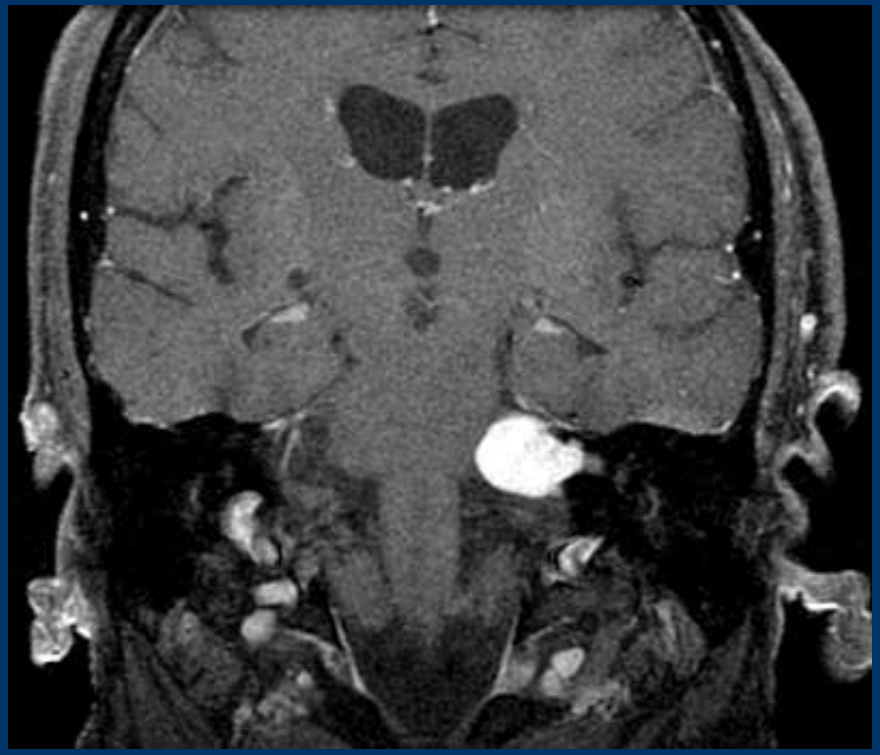

Intracochlear Schwannoma

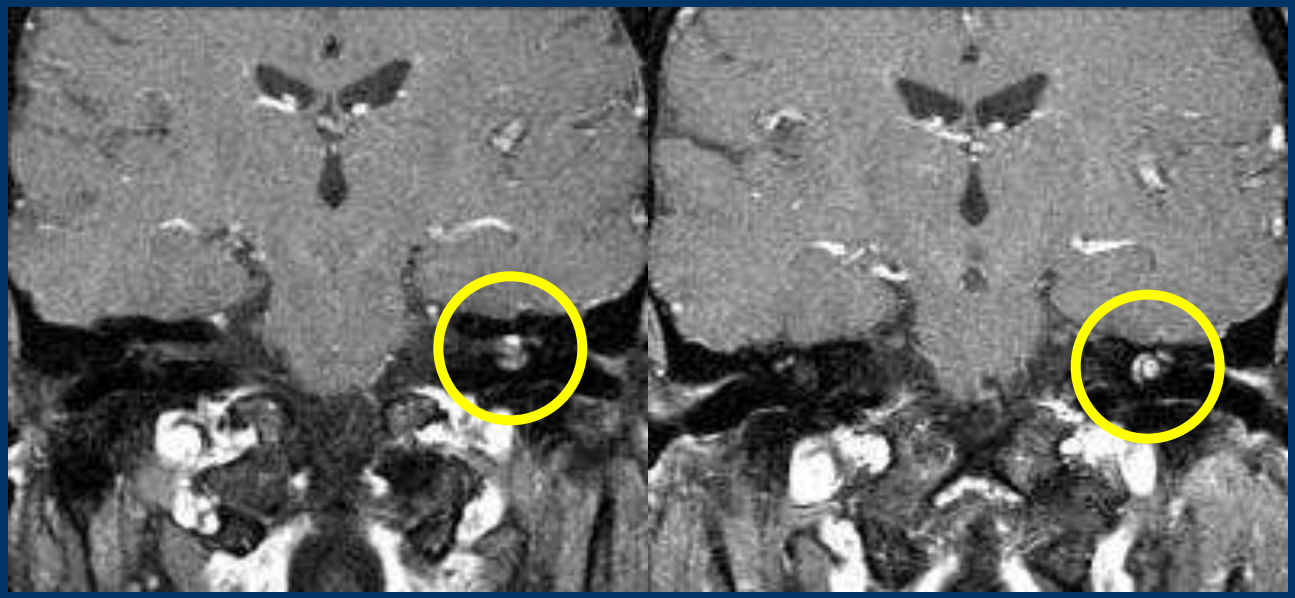

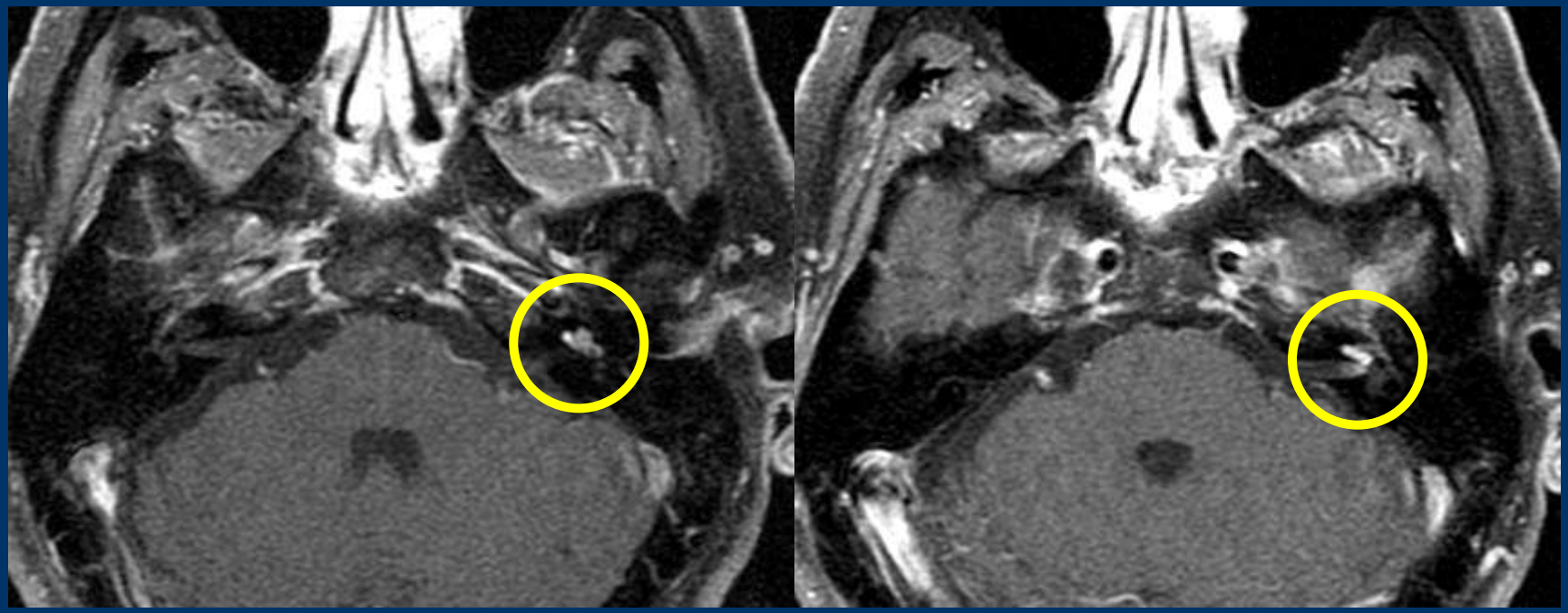

30 y/o F with 6wk h/o blurred vision

Craniopharyngioma

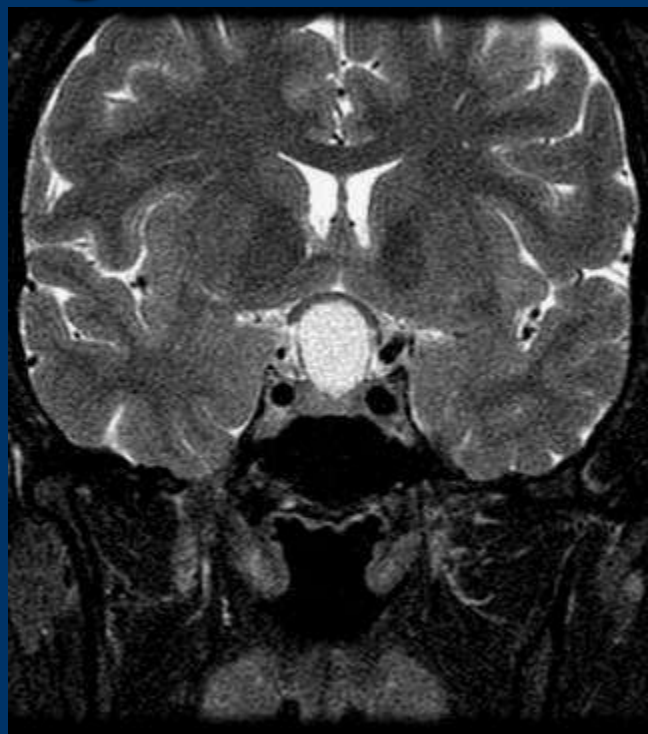

Introduction to Neuroimaging

BRAIN

Aaron S. Field, MD, PhD
Neuroradiology
University of Wisconsin–Madison